

2015

A Guide to Scleral Lens Fitting (2 ed.)

Eef van der Worp

College of Optometry, Pacific University

Follow this and additional works at: <http://commons.pacificu.edu/mono>



Part of the [Optometry Commons](#)

Recommended Citation

van der Worp E. *A Guide to Scleral Lens Fitting, Version 2.0* [monograph online]. Forest Grove, OR: Pacific University; 2015. Available from: <http://commons.pacificu.edu/mono/10/>.

This Book is brought to you for free and open access by the Pacific University Libraries at CommonKnowledge. It has been accepted for inclusion in Monographs, Reports, and Catalogs by an authorized administrator of CommonKnowledge. For more information, please contact gilmani@pacificu.edu.

A Guide to Scleral Lens Fitting (2 ed.)

Description

A new, updated version of the *Guide to Scleral Lens Fitting* has been launched recently. As the editor of the guide, I had the pleasure of working with an international team of over twenty experts in the field – from all over the world.

Personally it feels like the guide only now is finalized, after so many years since its first edition. What started as a ‘simple’ revision of this first edition ended up as a complete makeover of the entire guide. Most probably – almost literally – not a single sentence came out untouched. Although some questions surely remain in the scleral lens arena – the overall consensus and agreement on things is much better than it was back in 2010 at the time the first edition took shape. It tries to be a state-of-the-art resource – well balanced between the benefits that we know sclerals can have, and the risks and pitfalls that it involves.

As an illustration of the growing-up process: in terms of volume of publications on the topics, the reference list expanded from 2.5 to 5 pages in total. It seems that the amount of relevant publications since 2010 exceeds that of the number of publications before that time – a wealth of information – all of which of course were incorporated in the new guide. Based on the available literature and the priceless clinical input from the international board, a new guide is created that seems to be a comprehensive and complete overview of everything we know about the topic today in a useful format.

NOTE: *A corrected version has been posted as of January 5, 2016.*

[Access the first edition of this guide here.](#)

This publication is supported by an unrestricted educational grant from Bausch + Lomb.

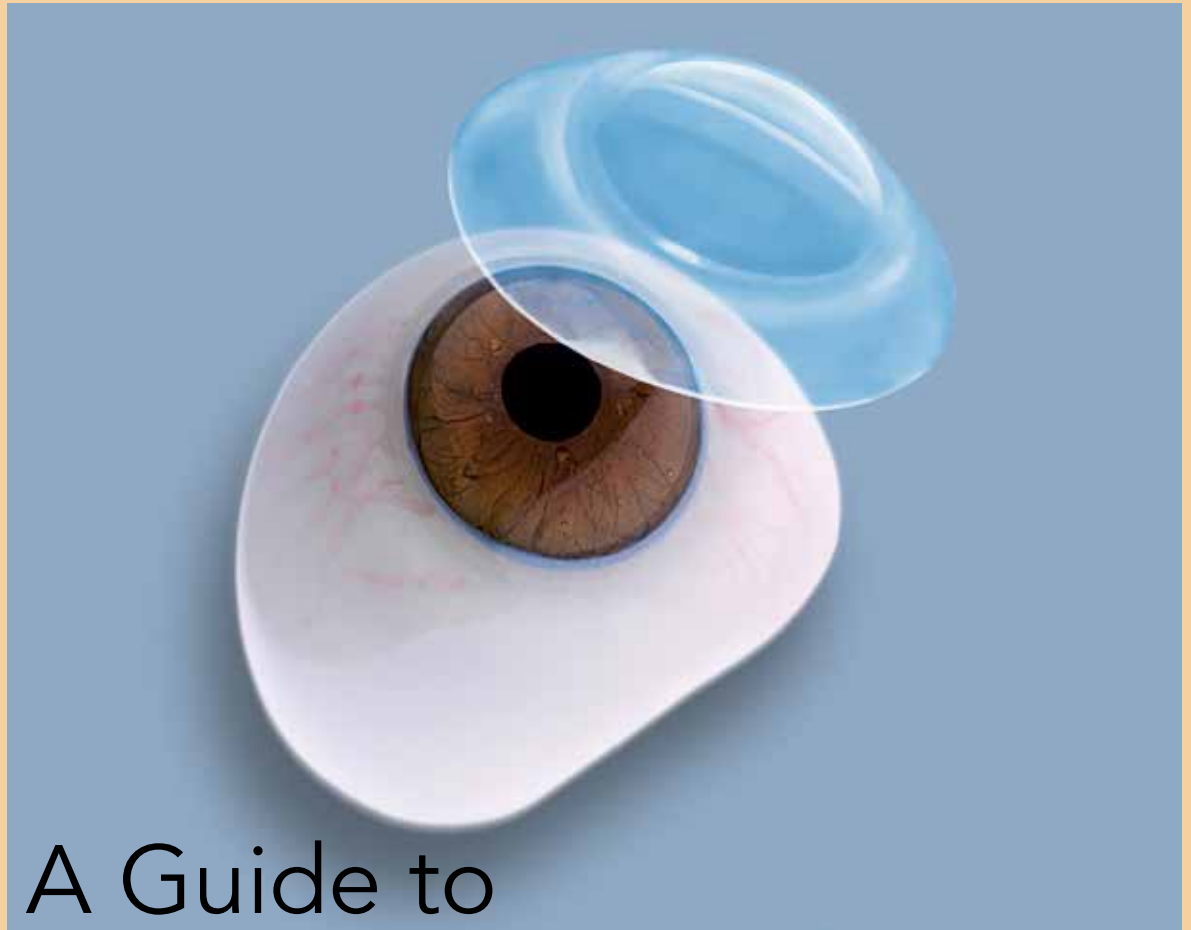Disciplines

Optometry

Comments

Eef van der Worp, BOptom, PhD FAAO FIAACLE FBCLA FSLS – Washington DC (USA)/Amsterdam (the Netherlands)

Eef van der Worp is an educator and researcher in the contact lens field. Eef received his optometry degree from the Hogeschool van Utrecht in the Netherlands (NL) and his PhD from the University of Maastricht (NL). He is affiliated with [Pacific University College of Optometry](#) (USA) and the [University of Maastricht](#) and is a visiting lecturer to many optometry schools. He resides both in Amsterdam (NL) and in Washington DC (USA).



A Guide to Scleral Lens Fitting

Version 2.0

Eef van der Worp
optometrist, PhD

A Guide to Scleral Lens Fitting

Contents

Preface	IV
I. Introduction	1
II. Anatomy and Shape of the Anterior Ocular Surface	9
III. Scleral Lens Design	18
IV. A Five Step Fitting Approach	27
V. Managing Scleral Lens Wear	44
Appendix	62
References	64

Editorial Board

Editor

Eef van der Worp, BOptom, PhD FAAO FIAACLE FBCLA FSLS – Amsterdam (the Netherlands)

Eef van der Worp is an educator and researcher in the contact lens field. Eef received his optometry degree from the Hogeschool van Utrecht in the Netherlands (NL) and his PhD from the University of Maastricht (NL). He is affiliated with the University of Maastricht as an associate researcher, is an adjunct Professor at the University of Montreal College of Optometry (CA) and is an adjunct assistant Professor at Pacific University College of Optometry (Oregon, USA).

Pacific University College of Optometry, Forest Grove, OR (USA)



Pacific University has been active in contact lens research over the last two decades and has been on the forefront of scleral lens education and research. The contact lens team at Pacific University College of Optometry consists of Patrick Caroline, Beth Kinoshita, Matthew Lampa, Mark André, Randy Kojima, Sheila Morrison, Maria Walker and Jennifer Coyle. Special thanks are due to Tina Graf from the Aalen University in Germany for all of her work and devotion toward the Pacific University Scleral Shape Study.

International Board

Stephen P. Byrnes, OD FAAO – Londonderry, NH (USA)

Steve Byrnes received his optometric training at The New England College of Optometry in Boston, MA (USA) and maintains a primary care private practice with specialization in contact lenses in Londonderry, NH (USA). He is an academic education consultant to many schools and colleges of optometry in the USA for Bausch + Lomb. He lectures internationally on rigid gas permeable contact lens design, fitting and problem-solving.

Gregory W. DeNaeyer, OD FAAO FSLS – Columbus, OH (USA)

Greg DeNaeyer practices at Arena Eye Surgeons with an emphasis on specialty contact lenses. He was a co-founder and past president of the Scleral Lens Education Society and is a Fellow of the American Academy of Optometry. He is a contributing editor for *Contact Lens Spectrum* and a contributor to *Review of Cornea and Contact Lenses*.

Donald F. Ezekiel, AM DipOpt DCLP FACLP FAAO FCLSA – Perth (Australia)

Don Ezekiel graduated from the University of Western Australia in Optometry in 1957. He completed his post-graduate studies in London (UK). While in London, he worked in the practice of contact lens pioneer Dr. Joseph Dallos, who taught him how to research and influenced him to make contact lenses for his patients. In 1967, he established a contact lens laboratory in Australia. He is an expert and a pioneer in scleral lens fitting.

Greg Gemoules, OD – Coppell, TX (USA)

Greg Gemoules received his optometry degree from the Illinois College of Optometry (USA). He moved to Texas and established his practice in Coppell, a growing suburb of Dallas (USA). He has established a large specialty lens practice and has several publications in the peer-reviewed literature. He is a pioneer in the use of optical coherence tomography (OCT) and wavefront-guided optics in the fitting of scleral lenses and has lectured at a number of conferences on the topic.

Jason Jedlicka, OD FAAO FSLS – Bloomington, IN (USA)

Jason Jedlicka is the Chief of the Contact Lens Service and an Associate Professor at the Indiana University School of Optometry. He is a diplomate in the Cornea and Contact Lens Section of the American Academy of Optometry and the immediate past president of the Scleral Lens Education Society.

Deborah S. Jacobs, MD – Boston, MA (USA)

Deborah Jacobs has been Medical Director at Boston Foundation for Sight since 2006. She earned her MS from Oxford University as a Rhodes Scholar and her MD from Harvard Medical School (USA). She completed her ophthalmology residency and fellowship in Cornea and External Disease at Massachusetts Eye & Ear Infirmary, where she is now a faculty member. She is an assistant clinical professor of Ophthalmology at Harvard Medical School.

Lynette Johns, OD FAAO

Lynette Johns was formerly senior optometrist at the Boston Foundation for Sight. She is an adjunct assistant professor at the New England College of Optometry (USA) and a fellow of the American Academy of Optometry and the Scleral Lens Society. She serves as a clinical and education consultant in specialty lenses of Bausch + Lomb Boston.

Craig W. Norman, FCLSA – South Bend, IN (USA)

Josh Lotoczky, OD FAAO

Chad Rosen, OD FAAO – Big Rapids, MI (USA)

Craig Norman is the Director of Research at the Michigan College of Optometry (MCO), Ferris State University. A graduate of the University of Minnesota's Physician Assistant of Ophthalmology program and a clinician for the past 30+ years, he has been involved in the development and evaluation of numerous products and technologies in the soft, GP and scleral lens category.

Josh Lotoczky is an Associate Professor at MCO. He earned his doctorate in Optometry from MCO in 2004 and completed a Cornea and Contact Lens residency the following year. He serves as the Chief of the Cornea and Contact Lens Services at the University Eye Center and is a Fellow of the American Academy of Optometry.

Chad Rosen is the Senior Clinical Fellow at MCO's Vision Research Institute. He completed a residency in Cornea and Contact Lens at Pacific University College of Optometry and then obtained Fellowship of the American Academy of Optometry. He has been involved in a variety of contact lens-related research projects and has lectured throughout the United States on various contact lens topics.

Jan Pauwels – Antwerp (Belgium)

Jacob H. van Blitterswijk – Arnhem (the Netherlands)

Cristian Mertz, BOptom FSLs – Utrecht (the Netherlands)

Jan Pauwels, optometrist, is owner of Lens Optical Technology and is working as a contact lens practitioner in three university hospitals in Belgium, UZA Antwerp, UZG Gent and CHU Liège. He completed his study in optics and optometry in Brussels (Belgium), and spends much of his time in fitting contact lenses on irregular corneas.

Jaap van Blitterswijk is a contact lens practitioner, designer, manufacturer and owner of several Dutch contact lens practices. He completed his study in Optics, Optometry and Contact Lenses in Rotterdam, the Netherlands. Jaap spends much of his time in educating specialty lens fitters.

Cristian Mertz graduated from the School of Optometry in Utrecht (the Netherlands). He started working in several Dutch contact lens practices specializing in medical contact lens fitting. He works for Microlens Contact Lens Technology as a clinical and educational consultant.

Kenneth W. Pullum, BSc FCOptom DipCLP FBCLA – Hertford (United Kingdom)

Ken Pullum graduated in 1974 at City University (UK). He was awarded the FCOptom in 1975, the DipCLP in 1978, fellowship of the BCLA in 2006 and life fellowship of the British College of Optometrists in 2013. He is principal optometrist in the scleral lens service at Moorfields, Oxford Eye Hospitals, and senior optometrist specializing in contact lens practice at the Queens Hospital, Romford, UK. He is also in private practice and director of Innovative Sclerals Ltd, a manufacturing company of scleral contact lenses, a subject on which he has lectured and written extensively.

Perry Rosenthal, MD – Boston, MA (USA)

Perry Rosenthal is founder of the Contact Lens Service at Harvard's Massachusetts Eye and Ear Infirmary, Polymer Technology Corporation (the Boston Lens® Products) and Boston Foundation for Sight. After being terminated from the Boston Foundation for Sight, he founded the Boston EyePain Foundation to continue his work in ocular neuropathic pain, including that traditionally known as dry eye disease, and is also a part-time Assistant Professor at Harvard Medical School.

Christine W. Sindt, OD FAAO FSLs – Iowa City, IA (USA)

Christine Sindt is a graduate of The Ohio State University College of Optometry (USA). She completed a disease-based residency at the Cleveland VA Medical Center (USA). She joined the Faculty of the University of Iowa Department of Ophthalmology and Visual Sciences (USA) in 1995, where she is currently an associate professor of Clinical Ophthalmology and director of the Contact Lens Service. She is the co-founder of the Scleral Lens Education Society.

Sophie Taylor-West, BSc MCOptom

Nigel Burnett-Hodd, BSc FCOptom DipCLP – London (United Kingdom)

Nigel Burnett-Hodd and Sophie Taylor-West both work at Nigel's Central London (UK) contact lens specialist practice, which specializes in challenging contact lens cases, particularly keratoconus, post-corneal graft and post-LASIK grief patients. Sophie Taylor-West has a keen interest in fitting corneo-scleral and hybrid contact lenses and also works part time at her own contact lens specialist practice in Brighton (UK). Nigel Burnett-Hodd is past-president of both the British Contact Lens Association and the International Society of Contact Lens Specialists.

Esther-Simone Visser, BOptom MSc

Rients Visser Sr – Nijmegen (the Netherlands)

Esther-Simone Visser graduated from the School of Optometry in Utrecht (the Netherlands) in 1995. She obtained her Masters Degree at City University in London (UK) in 2004. She joined The Visser Contact Lens Practice, working at several university hospitals in the Netherlands, where she continued to specialize in medical contact lens fitting. She subsequently joined the scleral lens fitting and development team of Rients Visser. She has published and presented widely on scleral lenses.

Rients Visser followed the study in Optics, Optometry and Contact lenses in Rotterdam (the Netherlands). He specializes in the medical application of contact lenses and is the founder of Visser Contact Lens Practice, which consists of 23 satellite locations, most of them situated in (university) hospitals. The scleral lens team counts eight optometrists and takes care of scleral lens patients from the Netherlands and abroad. Rients has presented and published widely on scleral lenses and multifocal contact lenses and has developed his own lens designs.

Preface and Acknowledgements

This guide is based on an extended literature search on the subject of scleral lens fitting as well as clinical input from experienced scleral lens fitters from around the world. It provides an overview of the latest knowledge and understanding of this exciting vision correction method. As an educator, I believe the guide presents an objective, neutral overview that is not biased in any way toward any fitting technique, industry partner or location—as different approaches exist in different parts of the world. Being slightly at a distance as an independent educator from any specific fitting technology or philosophy felt like an advantage in this process.

The input from the international editorial board who work with their respective lens designs and principles on a daily basis was paramount for composing this guide: not only did the input from the contributors and reviewers add tremendously to the content of this guide, their publications and presentations were also invaluable. The International Association of Contact Lens Educators (IACLE) contact lens course modules proved to be an excellent resource as well—both for understanding the anatomy of the anterior segment as well as for good basic understanding of scleral lenses—and they are highly recommended for eye care practitioners in contact lens practice. See the reference section at the end of the guide for details and a full overview of materials used for this guide.

In addition to the great clinical input from all members of the international board and the contact lens team at Pacific University College of Optometry, I would like to thank colleagues at a number of universities for their collaboration in a variety of scleral lens-related research projects: Langis Michaud at the University of Montreal (Montreal, Canada); Jan Bergmanson, William Miller and Norman Leach of the Texas Eye Research & Technology Center at the University of Houston College of Optometry, USA; Jose Manuel González-Mejome, Daniela Lopes Ferreira, Miguel, Faria-Ribeiro, Nery Garcia-Porta, Rute Araújo and the team at the Clinical and Experimental Optometry Research Laboratory at the University of Minho, Braga in Portugal for a variety of scleral lens-related studies and literature search on the topic. Also thanks to Ron Beerten and Elien Janssen of Procornea in the Netherlands for their valuable input.

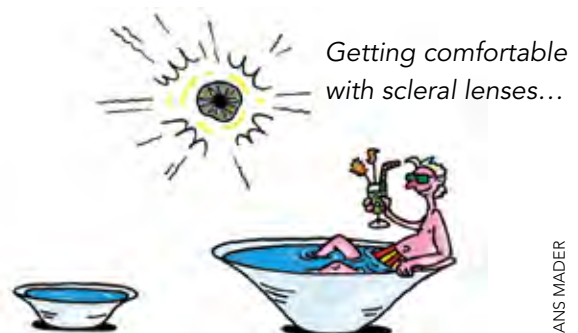Joshua Lotoczky, Chad Rosen and Craig Norman of the Michigan College of Optometry provided the scleral lens fit scales, which is a fantastic addition to the 2.0 version of this guide. And special thanks is due to Lisa Starcher for her work in copy editing and improving the text of the scleral lens guide.

Specifically, I would like to thank Rients and Ester-Simone Visser for introducing me to scleral lenses, back when I was a student, and for their ongoing support and their invaluable input regarding scleral lenses and scleral lens wear. Also, I would like to thank Lynette Johns for being my sparring partner in composing this new version of the guide. Her clinical input was invaluable.

This guide serves as an introduction to scleral shape, scleral topography and scleral lens design as well as a generic guide to fitting scleral lenses to help the practitioner get more comfortable with the concept of scleral lenses. It provides a general overview, supported by the main experienced scleral lens fitters worldwide. Its goal is to give practitioners a framework to approach and to integrate scleral lens fitting into their practices. Being a general overview, it can never cover all of the specific scleral lens designs available and cannot be a fitting guide for all lens types available.

Modern scleral lens fitting still is in its infancy, which makes it a modality with great potential. However, fitting scleral lenses is not very black-and-white, and many differences exist among fitters, cultures, manufacturers and countries. This clinical guide tries to find “common ground” among the mentioned philosophies. For specific lens fitting rules and guidelines, the lens manufacturers and the laboratories’ consultants and specialists should be used to their fullest potential. In 2006, it was stated in the mentioned contact lens course on specialty lens fitting that, “Although fitted by few contact lens practitioners, scleral lenses can play a major role in providing an optimal visual correction.” This picture has changed dramatically in the meantime, as the modality has gained a lot of momentum. This 2.0 version of the guide includes an update on the latest developments in the dynamic field of this vision correction method with scleral lenses, and it provides an overview of managing the scleral lens patient.

~ Eef van der Worp



I. Introduction

- Terminology
- Indications

The concept of optically neutralizing the cornea with an enclosed liquid reservoir over its front surface was first proposed in 1508 by Leonardo da Vinci. This section briefly covers the history of scleral lenses, followed by currently used terminology and the broad spectrum of indications for fitting scleral lenses.

It is in the interest of the patient that more practitioners get familiar with the modality to serve patients with the best optical correction available—which is often a scleral lens for the more challenging eyes.

Large diameter contact lenses that have their resting point beyond the corneal borders are believed to be among the best vision correction options for irregular corneas; they can postpone or even prevent surgical intervention as well as decrease the risk of corneal scarring. For true clearance of the cornea, without any mechanical involvement, it seems advised to avoid any contact between the lens and the cornea by bridging over it. These lenses are technically not “contact lenses,” at least not with the corneal surface—which can be one of the biggest advantages of this modality.

A number of years back, only a handful of very specialized lens fitters around the world were capable of fitting scleral lenses successfully, and only a few manufacturers were making scleral lenses. Now, many contact lens manufacturers have scleral lens designs in their arsenal. New insights into corneo-scleral junction and anterior scleral shape as well as improved manufacturing processes allow for better design, make lenses more reproducible and decrease costs. Combined with better lens materials, this has contributed to better ocular health, longer wearing time and ease of lens fit. Many special websites and organizations are devoted to scleral lenses, and conferences and the ophthalmic literature are frequently reporting on scleral lens fitting. It is in the interest of the patient that more practitioners get familiar with the modality to serve patients with the best optical correction available—which is often a scleral lens for the more challenging eyes.



A scleral lens hand-held

The first blown scleral shells and ground scleral lenses made of glass were produced in the late 19th century. In the early 20th century, Carl Zeiss of Jena, Germany offered a set of four lenses that allowed trial fitting of lenses with a known specification. This company was the first to experiment with plastic lenses and was granted a patent in 1923 for their manufacture from ‘cellon, celluloid or an organic substance with similar mechanical and optical properties’. The earliest report on fitting of polymethyl methacrylate (PMMA) scleral lenses appears to have been made by Thier in 1939, and early adopters of plastic materials included Feinbloom, Obrigg and Györrfy. Plastic lenses were far less fragile than glass and more



Glass blown Carl Zeiss Jena scleral lens trial set from the early 1920's

Indications for scleral lens fitting have been evolving over the last few years, emerging from a lens for severely irregular corneas only to a much broader spectrum of indications.

easily modified to achieve an optimum fit. In the 1930s, Dallos developed the technique for taking eye impressions, the casts of which were used to produce molded glass lenses that had a well-fitting scleral zone, according to Pearson (2014).

Plastic lenses now could be manufactured on a lathe-cut basis and in a much more accurate manner to mimic the anterior shape of the eye. The use of oxygen permeable lenses, as first described by Ezekiel in 1983, was another breakthrough, since this brought major improvements in ocular health. The development of the smaller, corneal gas permeable lenses and later of soft lenses, in the meantime, temporarily stopped further development of scleral lens

fitting, but the scleral lens is now fully back on the agenda as an option for more challenging eyes. Many scleral lens options are now available to practitioners, including front toric, back toric, bitoric, quadrant specific and even multifocal lens designs for the correction of presbyopia.

Because scleral lenses bridge the cornea, comfort of lens wear is really one of the most spectacular benefits of these lenses. Some of our scleral lens patients complained to their physicians about why they weren't referred for scleral lenses earlier, since comfort of lens wear is so good. We also see that many keratoconus patients with a scleral lens on one eye want to be fitted with a scleral lens on the other eye too instead of a corneal GP lens—again because of comfort.

Esther-Simone Visser and Rients Visser

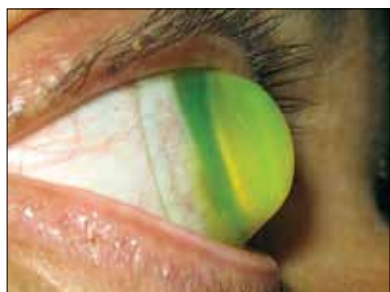Terminology

Terminology for scleral lenses and the definitions for different lenses and lens types have gone through an evolution in recent years. In the past, this has been diverse, locally determined, oftentimes arbitrary and at times confusing. The Scleral Lens Education Society (SLS) has more recently recommended internationally recognized nomenclature for describing scleral lenses according to size and fit characteristics. The recommendations of the SLS are based on the lens' resting point on the ocular surface, not on lens diameter. Simply put, if a rigid gas permeable (GP) lens rests completely on the cornea, it is called a corneal lens. A lens that partly rests on the cornea (centrally or peripherally) and partly on the sclera is called a corneo-scleral lens. A lens that rests entirely on the sclera is a scleral lens, no matter how large that lens is.

The SLS advises against using diameter classification in scleral lens nomenclature, as this would not suffice in cases of extremely large or small eyes, for instance.

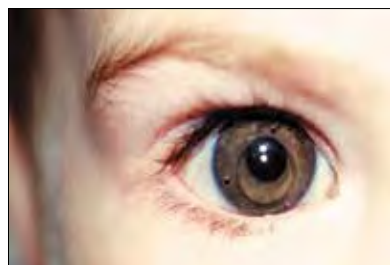The described nomenclature seems pretty straightforward based on resting zone on the ocular surface. The confusing part to some degree for eye care practitioners may be that some lenses with, for instance, a 14.5 mm diameter that rests partly on the cornea and partly on the sclera fall within the corneo-scleral lens category, but a lens with the exact same diameter that entirely has its resting zone on the sclera is a (full) scleral lens by definition. It is important to make this distinction, as it is generally agreed upon that in terms of fitting procedure, physiological management of the lens and other recommendations—a corneo-scleral lens is a different entity than a full scleral lens with its landing zone entirely on the sclera.

When there is full landing on the sclera, further distinctions of the scleral lens group, although arbitrary, would include mini-scleral and large-scleral lenses. These distinctions emphasize differences in central corneal clearance and other fitting characteristics. As an example,



GREG DENAEYER

Large diameter scleral lens holding a large tear reservoir



DON EZEKIEL

Pediatric aphakic scleral lens

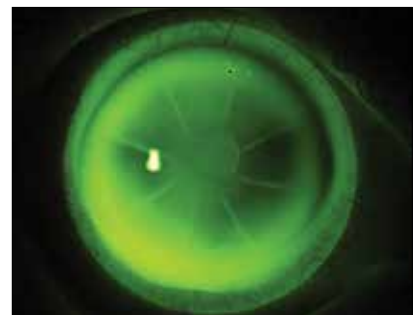
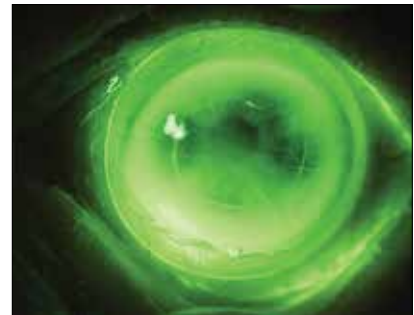
a lens that is 6 mm larger than the horizontal visible iris diameter (e.g., has up to 3 mm of bearing on the sclera on each side of the cornea) is classified as a mini-scleral lens. A lens that is more than 6 mm larger than the visible iris diameter is classified as a large-scleral lens. For an eye with an average corneal diameter of 12 mm, an 18 mm lens that lands exclusively on the sclera would be a mini-scleral lens, while a lens larger than 18 mm for the same eye would be a large-scleral lens. In this guide, the term scleral lens is used to describe the broad range of all large diameter lens modalities, but if a specific lens type is referred to, then that terminology (e.g., corneo-scleral, full-scleral, mini-scleral and large-scleral) will be used.

The biggest difference apart from landing area and location among the smaller and the larger diameter scleral lenses is the amount of clearance that can be created beneath the central lens. In small diameter lenses, the tear reservoir capacity is typically small, while in the large diameter scleral lenses, the tear reservoir capacity is almost unlimited. But all types of (mini-) scleral contact lens designs have the ability to promote good apical clearance to some degree compared to corneal contact lenses. This can reduce mechanical stress to the cornea, which is considered a major advantage of any type of scleral lens.

Terminology

	Subdivision	Bearing
Corneal		Lens rests entirely on the cornea
Corneo-Scleral		Lens rests partly on the cornea, partly on the sclera
(Full) Scleral	Mini-scleral <i>Lens is up to 6mm larger than HVID</i>	Lens rests entirely on the sclera
	Large-scleral <i>Lens is more than 6mm larger than HVID</i>	

The Scleral Lens Education Society (SLS) introduced an internationally recognized nomenclature for describing scleral lenses based on the resting zone area of the lens on the ocular surface, not on lens diameter.



Corneo-scleral lenses on post RK corneas

SOPHIE TAYLOR-WEST

Indications

Indications for scleral lens fitting have been evolving over the last few years, emerging from a lens for severely irregular corneas only to a much broader spectrum of indications, which can be broadly categorized as (van der Worp 2014, Schornack 2015):

1. Vision Improvement

Correcting the irregular cornea to restore vision is the main indication for fitting scleral lenses. The largest segment within this category is corneal ectasia, which can be subdivided into two groups. First is the primary corneal ectasia group (McMahon 2013), which includes conditions such as keratoconus, keratoglobus and pellucid marginal degeneration. The secondary ectasia group consists of post-refractive surgery, including post-laser assisted in-situ keratomileusis (LASIK), post-laser assisted epithelial

Keep in mind that corneo-sclerals are easier for part-time users compared to corneal GPs due to little or no adaptation. The larger diameter means less lid interaction—and very little adaptation is necessary.

Jason Jedlicka 2010b

keratoplasty (LASEK), post-photorefractive keratectomy (PRK) and post-radial keratotomies (RK), and corneal trauma. A recent study by Lo et al (2014) looked at scleral lens use after unsuccessful refractive surgery results. The follow-up period was 14.4 months; all eyes achieved significant improvement in best corrected visual acuity, and none of the patients in the study discontinued scleral lens wear. This poses the lenses as a serious consideration for these corneas, the authors concluded.

The primary ectasia group also consists of corneas that have been treated surgically to manage the ectasia in various ways—such as intrastromal ring implants and, more recently, corneal crosslinking.

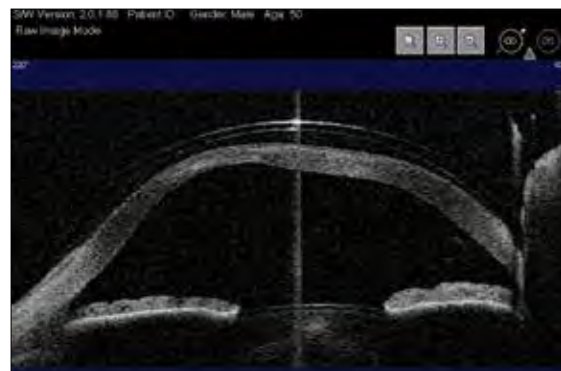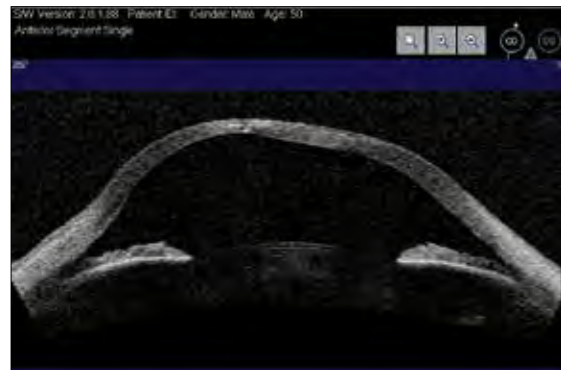Visser et al (2014) studied the latter group and concluded that scleral

lenses are well accepted in these patients and can be an excellent indication to restore vision. Corneal transplants for primary ectasia, especially the penetrating keratoplasty technique, often require a contact lens post-surgery to fully restore vision. A scleral lens may be indicated in many of these cases, especially as it can help to preserve these fragile corneas and prevent mechanical strain. This may require extra attention in terms of creating adequate clearance (see chapter IV, step 2) to prevent the lens from touching the fragile cornea.

Other irregular cornea indications with the primary goal to restore vision include post-trauma corneas. Eyes with significant scarring and severe irregularity due to trauma can achieve excellent vision with scleral lenses—often to the surprise of both the patient and the eye care practitioner. This seems particularly true for corneal scars as a result of corneal infections, like in Herpes simplex.

Corneal degenerations or dystrophies, such as Terrien’s marginal degeneration and Salzmann’s nodular degeneration, can also be an indication for scleral lenses.

In some cases, patients with high refractive corrective errors (both hyperopic and myopic) and cases of aphakia that cannot be successfully fit with corneal lenses can benefit from scleral lenses (Visser 1997, Pullum 2013). Other vision-related indications include scleral lenses for corneal astigmatism. A more recent development is to consider a scleral lens as a first lens option for moderate to severe corneal astigmatism, as opposed to a corneal GP lens to restore vision—although different opinions in this regard exist in different part of the world. A relatively new, but surprisingly well accepted modality, is scleral lenses for presbyopia. Due to the superb optical quality of the large GP lens, correction of any corneal irregularities, good lens centration and typically minimal lens movement —simultaneous design scleral multifocal lenses can offer some patients a good optical system, for both distance and near. On occasion, scleral lenses can be designed with horizontal prisms, as they are very stable on the eye. This is usually not possible with corneal lenses because of lens rotation (Millis 2005).



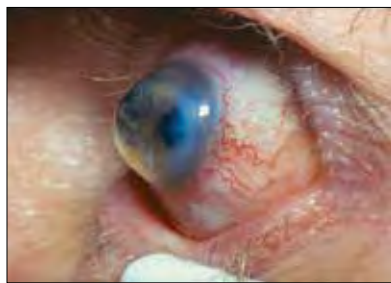OCT images of a severely irregular cornea without and with a scleral lens for visual rehabilitation

GREG GEMOULES

2. Ocular Surface Protection

“Dry eye” is becoming an increasingly important indication for scleral lenses. A large group of exposure keratitis/ocular surface disease patients can particularly benefit from scleral lenses because of the retention of a fluid reservoir behind the scleral lens. Sjögren’s syndrome is one of the most common scleral lens indications within this category. But within this group are also conditions such as Stevens-Johnson Syndrome, graft-versus-host disease, exposure keratopathy, ocular cicatricial pemphigoid, neurotrophic corneal disease and atopic keratoconjunctivitis. Apart from ocular surface protection in some practices, healing of epithelial defects is another prime reason for using scleral lenses, as in cases of persistent epithelial corneal defects, for instance. Managing these lenses and corneas is usually performed in specialized clinics.

Also, if lid closure is incomplete, such as in eyelid coloboma, exophthalmos,



Extreme case of pellucid marginal degeneration—a good indication for scleral lenses

VISSER CONTACT LENS PRACTICE

ectropion, nerve palsies and after lid retraction surgery (Pullum 2005), a scleral lens may be a good indication. In addition, in cases of trichiasis and entropion, scleral lenses have shown to be effective in protecting the ocular surface. In acoustic neuroma resection with resultant lagophthalmos and occasional corneal anesthesia, scleral lenses have also been reported to show excellent results.

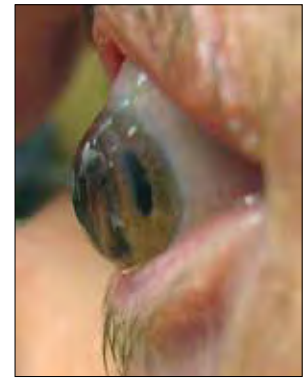
Some of the largest scleral lens fitting centers in the world indicate that they fit equal or more scleral lenses for ocular surface disease than for the irregular cornea. Some specialized “dry eye clinics” also seem to have embraced scleral lenses as one of the treatment options available for patients with ocular surface disease. It should be noted,

though, that while the technical fitting of scleral lenses in these eyes is not more complex than in any other eye, management of the disease, and especially managing, guiding and coaching the dry eye patient, is often a different story that requires extra time, care and effort on the side of the eye care practitioner. Typically, this is performed in specialty lens clinics that have a long track record in managing ocular surface disease.

More recently, scleral lenses have also been applied in experimental settings to deliver pharmaceuticals to the anterior surface for different reasons. One such indication is the application of prophylactic preservative-free antibiotics while the ocular surface recovers/heals, such as the treatment of persistent corneal epithelial defects with scleral lenses and an antibiotic adjunct (Lim 2013). Jacobs et al (2009) discussed the possibility of using scleral lenses as a novel drug delivery system for bevacizumab to treat neovascu-

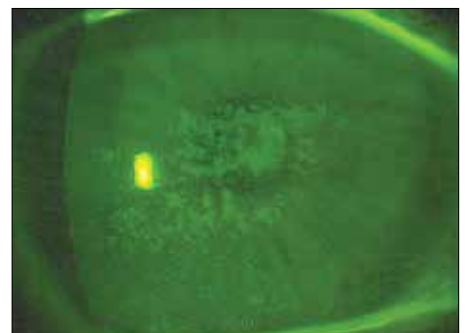
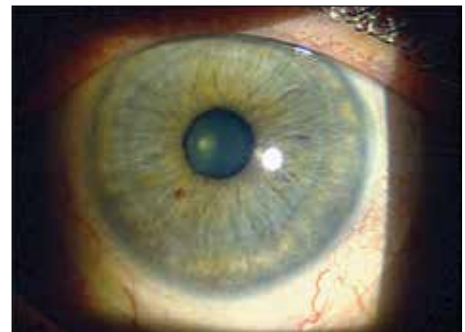A case of a 55-year-old dry eye patient fitted with mini-scleral lenses (shown in photos to the right), resulting in excellent comfort and relief of the dry eye symptoms. The lens also includes a multifocal front surface that consists of a 2.0 mm central add zone of +2.00D. The visual acuity with this lens is 20/20 for distance and 20/25 for near.

Jason Jedlicka



CHRISTINE SINDT

Corneal graft, unfittable with any other lens type than a scleral lens



JASON JEDLICKA

It seems that age restrictions are virtually non-existing in scleral lenses. The Boston Foundation for Sight reported on a retrospective study of successful scleral lens fitting in 47 eyes of 31 pediatric patients aged 7 months to 13 years—with ocular surface disease being the predominant indication rather than refractive disorders.

Gungor et al 2008

larization. Also, the application of scleral lenses with low levels of sodium channel modulators has been proposed as a form of pain mediation by Rosenthal (2009b).

3. Cosmetics/Sports

Hand-painted scleral lenses have been used for cosmetic purposes in a variety of cases, often related to atrophied bulbi (Otten 2010). These painted lenses have been based on PMMA materials, as hand-painted gas permeable scleral lenses have not been available to date. Painted lenses have also been used to reduce glare in aniridia and albinism (Millis 2005), although this would technically fall under the vision improvement category rather than

under cosmetic indications. Scleral lenses have also been used for cosmetic reasons in cases of a ptosis, as a large diameter scleral lens with significant vault increases aperture size.

Scleral lenses may be helpful for those involved in active water sports, such as water polo or canoeing, diving and water skiing, as well as for other vigorous sports activities or for those that involve exposure to dusty environments.

Corneal GP Lenses or Scleral Lenses?

Why would any eye care practitioner fit a scleral lens rather than corneal GP lens, which is clinically well-proven and has a long track record? First of all, the cornea, which is one of the most sensitive parts of the human body, is bypassed as a landing area with scleral lenses. In order for the cornea to remain transparent—its main characteristic—corneal nerves lack the myelinated sheath (which is nontransparent) that is present in most other nerves in the human body. But this also leaves the nerves exposed, and mechanical stress such as with a corneal contact lens can trigger the nerves, causing discomfort.

Advantages of scleral lenses with advancing ectasia are that the ectasia may advance underneath a well bridging/vaulting lens and the patient will never observe the difference nor require a refitting.

Lynette Johns

The conjunctiva and sclera show a very low sensitivity, which makes them very suitable for lens landing. So while at first glance choosing scleral lenses may be counterintuitive because of size, scleral lenses are in fact experienced as very comfortable. In addition, scleral lenses have very limited movement on-eye. When first exposed to a scleral lens, patients almost, without exception, show their positive excitement about comfort of lens wear.

Scleral lenses basically do not touch the cornea, and therefore there is little or no corneal distortion (e.g., corneal warpage) with scleral lens wear. In fact, scleral lens wear has been reported to be an excellent way of letting the cornea return to its baseline flattening after (PMMA) corneal lens wear, orthokeratology, and other cases in which the corneal surface was altered—either in a wanted or in an unwanted fashion.

In the Collaborative Longitudinal Evaluation of Keratoconus (CLEK) study in the United States, 1,209 keratoconus patients were observed over a period of eight years at several sites around the country. Results from the CLEK study show that scar formation in keratoconus may lead to a loss in contrast sensitivity, which may create a vision problem. This is especially a concern because keratoconus patients already have increased higher-order aberrations, primarily vertical coma, that may result in reduced contrast sensitivity. Baseline factors predictive of incident scarring included corneal curvature greater than 52.00 D, contact lens wear, marked corneal staining (without lens) and a patient age of less than 20 years (Barr 1999). Avoiding

Another valid point as to why comfort of scleral lenses is so good is the fact that with large diameter lenses there is much less lid interaction with the lens. Corneal lenses are uncomfortable not only due to the lens contact with the cornea, but also because on blinking the lids rub against the edges of the lens, making them move around and feel scratchy. Because the edges of scleral lenses are tucked away under the lids in their natural position, this issue is eliminated.

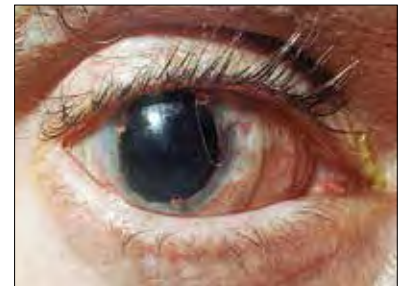*Sophie-Taylor-West and
Nigel Burnett Hodd*

pressure on the apex of the cornea with contact lenses seems preferable. This appears especially true in the case of a central keratoconus, since a central scar almost certainly leads to a loss in visual acuity.

Keratoconus patients typically have high levels of toricity, which in theory would benefit from back toric corneal GP lenses, but in reality these lenses seem to have little application. In a back toric lens design, the toric curvatures and corresponding power correction meridians are 90 degrees apart. This is often not the case in keratoconus, though, especially in moderate and advanced cases. A scleral lens, vaulting over the cornea, can help correct these irregularities. Also, scleral lenses typically have large optical zones, which make them more forgiving in terms of visual function if the lens decenters. This is especially important in patients with keratoglobus or decentered cones (Bennett 2009). Generally speaking, scleral lenses tend to center better on the eye than smaller corneal GP lenses do.

Corneal GP lens fitting has evolved and improved dramatically over the last 10 years with the addition of sophisticated lens designs based on corneal topography, such as highly aspheric and quadrant specific lens designs. It has become increasingly challenging, though, to fit these highly complex lens geometries. Technically, manufacturers are able to make these, but fitting them seems to be more and more the domain of a very select group of specialists. Large regional differences worldwide exist in that regard.

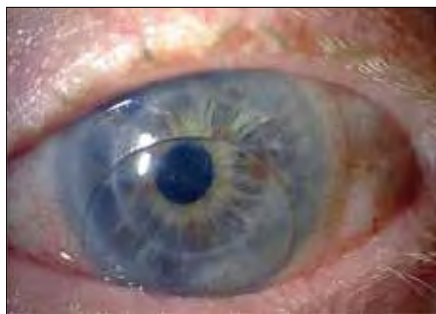Despite the new developments in the corneal GP lens field, reducing mechanical stress on the cornea is a challenge with every keratoconus lens fit, even for the experienced contact lens practitioner. In many cases, a scleral lens can be an excellent option to restore vision. For true corneal clearance without any mechanical involvement, and for better optics, it seems advised to avoid any contact between the lens and the cornea by bridging or vaulting over it. A good example of this may be keratoplasties (see next item). Because of the highly complex corneal shapes that can result from keratoplasty procedures, fitting a scleral lens has become the first lens of choice in some practices—despite the extra oxygen challenge this may bring, as will be discussed later in this guide. The shape of the sclera remains the same for the post-surgical as the normal eye, and bridging over the complex cornea is typically relatively easy with a scleral lens device.



Corneal trauma with iris loss fitted with a scleral lens

Scleral Lenses or Surgery?

Corneal ectasia, including keratoconus, is the main indication for fitting scleral contact lenses to restore vision. The National Keratoconus Foundation in the USA (2014) estimates that about 15 percent to 20 percent of keratoconus patients will eventually undergo corneal transplant surgery for the condition. The main form of surgical intervention to reduce the effect of keratoconus is a keratoplasty. The survival rate of penetrating corneal grafts is 74 percent after five years, 64 percent after 10 years, 27 percent after 20 years and is very limited at 2 percent after 30 years (Borderie 2009). Partial keratoplasties (lamellar keratoplasty), in which only the anterior portion of the cornea is removed, may help overcome the rejection problems, but a suboptimal visual outcome continues to be a concern (Jedlicka 2010a). Corneal edema is a



Poor corneal GP lens fit on a post-penetrating keratoplasty

Large diameter contact lenses that have at least part of their resting point beyond the corneal borders are believed to be among the best vision correction options for irregular corneas. They can often postpone or even prevent surgical intervention and may also decrease the risk of corneal scarring.

consideration post-grafting, as the endothelial health is potentially compromised after the surgery. Special attention to oxygen supply and recognition of symptoms is indicated in these patients (see 'Hypoxia and Edema' section in chapter V).

But even when medically successful and without complications, many patients post-keratoplasty still need a contact lens, usually a GP lens or possibly a scleral lens, to restore vision because of irregularities and high corneal astigmatism. This can be a huge disappointment for the patient, and patients should be well informed about this in advance.

The newest technology in the field of keratoconus management is corneal cross-linking. The therapy aims at halting the progression of keratoconus by applying Riboflavin (vitamin B-12) to the cornea and exposing the eye to UV-A radiation. This promotes creation of additional cross-links between the collagen fibers in the cornea. The short-to intermediate-term results seem very promising; however, while it can halt progression, the corneal changes found in keratoconus cannot be restored to baseline using this technique. The treatment aims at stopping the progression of the keratoconus. Therefore, often some form of vision correction is still needed after the procedure to optimize vision. Visser et al recently (2014) performed a study showing that scleral lenses were well tolerated and could be worn successfully after CXL procedures in all 18 patients followed for one year after the

procedure, with an average wearing time of 16 hours per day.

It is estimated that the vast majority of corneal ectasia patients will need GP lenses, corneal or scleral, at some point in life to achieve acceptable vision. A study by Smiddy et al (1988) found that 69 percent of patients who were referred for a keratoplasty could be successfully fit with contact lenses without surgery. A study by Baran et al (2012) found in a cohort of 89 ectasia patients after selection, that all candidates could be fitted with a scleral lens device, and a satisfactory fit was achieved. These statements seem to indicate a need for eye care practitioners to evaluate all contact lens options first before referring a patient for surgery. It is therefore advised to always evaluate how much visual acuity improvement can be gained with a variety of contact lenses, including scleral lenses, before referring the patient for a corneal transplant, as was suggested by DeLoss et al (2014).

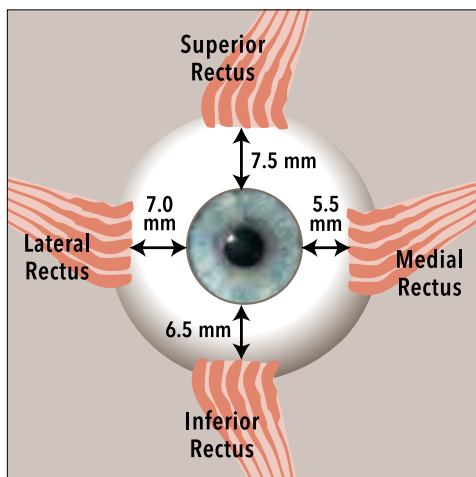
Key points:

- Indications for scleral lenses have evolved from a lens for the highly irregular cornea only to a broad range of indications, including moderate corneal irregularities, corneal protection, dry eye, high ametropia and cosmetic reasons.
- Even when medically successful and without complications, many patients post-corneal surgery still need a contact lens to restore vision because of corneal irregularities and astigmatism.
- To prevent corneal mechanical involvement by the contact lens, one can fit a scleral lens that will bridge or vault over the entire cornea.

II. Anatomy and Shape of the Anterior Ocular Surface

- What does the anterior ocular surface tissue consist of?
- What is the shape of the corneo-scleral junction and anterior ocular sclera?

The need for scleral lenses appears to be ever increasing lately. But, we need to know about the anatomy and the shape of the anterior ocular surface area to enable adequate scleral lens fitting.



Anterior Ocular Surface Anatomy

Textbook knowledge tells us that when looking at the anterior ocular surface, it appears that in the temporal, superior and inferior direction there is roughly 7.0 mm of space between the limbus of the cornea and the insertion of the rectus eye muscles (7.0 mm, 7.5 mm and 6.5 mm, respectively). However, on the nasal side there is only about 5.5 mm of space. This is referred to as the spiral of Tillaux, after the French physician who first described this phenomenon. With an average corneal diameter of close to 12 mm, this means that for the normal eye, the maximum physical diameter horizontally that a scleral lens can have before it may interfere with the location of the eye muscle insertion is about 24 mm, assuming limited or no lens movement.

Eye muscles insert beneath the conjunctival tissue and Tenon's capsule onto the sclera. Because of the anatomical location of the eyeball in the orbit, the temporal, inferior and superior rectus eye muscles wrap around the globe and stay in contact with it at all times, regardless of eye movements. The nasal eye muscle, on the other hand, comes loose from the globe with a medial eye movement despite its more anterior position of insertion on the eyeball. In a chapter of the book *Contact Lenses* by Phillips and Speedwell, Pullum (2005) states that “with large diameter scleral lenses, this could theoretically mean that a lateral movement of the lens on the eye or a slight lift of the lens off the cornea can occur.”

Conjunctival Anatomy

It is actually on the conjunctiva that scleral lenses land. But because the conjunctiva has no structure in itself and follows the scleral contour, the shape of the anterior eye beyond the corneal borders in scleral lens fitting is referred to as “scleral shape.” The conjunctiva is a mucous membrane consisting of loose, vascular connective tissue that is transparent. It is loose to allow free and independent movement over the globe. The conjunctiva consists of an epithelial and a stromal layer. At the limbus, the five layers of the corneal epithelium form into 10–15 layers of the conjunctival epithelium. The surface cells of the conjunctival epithelium have microplicae and microvilli, and the surface is not as smooth as the corneal sur-

In the temporal, superior and inferior direction there is roughly 7.0 mm of space between the limbus of the cornea and the insertion of the eye muscle; however, on the nasal side there is only 5.5 mm of space.

face. The conjunctival stroma is made up of loosely arranged bundles of coarse collagen tissue. In older age groups, the conjunctival epithelium seems to be more irregular from a morphological standpoint.

The thickness of the conjunctiva seems to vary significantly—among individuals and also among different studies, the outcome seems to vary. This may be due to the fact that it is hard to measure the thickness of such a soft mucous membrane. Recent OCT studies by Zhang et al (2013) in Chinese eyes have revealed that the average conjunctival thickness (epithelial and stromal conjunctiva together) is in the 240 micron range—however, in their study population (ages 28 to 76), this ranged from a minimum of 140 microns to a maximum of 304 microns. Age demonstrated a significant correlation with conjunctival thickness, showing a reduced thickness with time. However, between the ages of 20 and 60, only a faint decrease of conjunctival thickness was seen—followed by a sharp decrease after the age of 60. No difference in conjunctival thickness for gender was found. In this study, the lower temporal conjunctiva was measured. Reasons for this were that the conjunctiva and Tenon's capsule merge within 3 mm of the limbus, and also because the lower temporal conjunctiva is easily exposed, and muscle interference is minimized. More work into conjunctival thickness could potentially be helpful in better understanding scleral lens fitting.

It is actually the conjunctival surface, or Tenon's capsule, that is the landing plane for scleral lenses. But since the conjunctiva has no structure (e.g. it follows the scleral contour), the shape of the anterior eye beyond the corneal borders is referred to as "scleral shape."

Tenon's Capsule

Beneath the conjunctiva is Tenon's capsule, also called fascia bulbi: a thin, fibroelastic membrane that emerges shortly after the limbus and extends out over the globe. It separates the eyeball from the orbital fat, forming a socket in which the eyeball moves (Bergmanson 2015). At the limbus, Tenon's capsule is inseparable from the subconjunctival tissue and underlying episclera, but it becomes thicker about 3 mm from the limbus, where it is freely mobile over the underlying episclera. It is said that the thickness of Tenon's capsule

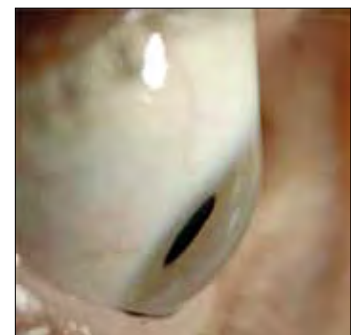in front of and over tendon insertions is responsible for the glistening, bright eyes of children and young adults, and it seems to thin with age (Watson 2013). Moving backward on the globe, away from the limbus, Tenon's capsule ensheaths the extraocular recti muscles.

If the conjunctival layer is disregarded, it is actually this Tenon's capsule that the large diameter lens' periphery (haptic zone) lands on, rather than on the sclera. Hence, in theory, the term "conjunctival lens" or "Tenon's lens" from an anatomical standpoint would be more appropriate than "scleral lens."

Scleral Anatomy

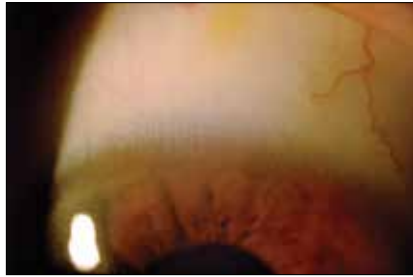The opaque sclera forms the main part of the eyeball and converts into the transparent cornea anteriorly on the eyeball. Duke-Elder (1961) reported that the scleral thickness is 0.8 mm at the limbus, 0.6 mm in front of the rectus muscle insertions, 0.3 mm behind the rectus muscle insertions, 0.4–0.6 mm at the equator of the globe and 1.0 mm near the optic nerve head.

The scleral radius is in the 12.3 to 13.3 mm range (temporally versus nasally) for the average eye—as a reference, the average central corneal radius is 7.8 mm (Choi 2014). The equatorial length of the eyeball is 24.1 mm transversely and 23.6 mm vertically. This implies that the scleral shape is not equal in all meridians. The sclera is relatively inactive metabolically, but is rather durable and tough. There are only limited blood vessels and nerves in the sclera, and thus it is less sensitive than the cornea.



A normal limbal-scleral shape profile

PATRICK CAROLINE



Limbal area with Palisades of Vogt

Before entering the “real” sclera, going from outer to inner layers, the first layer is actually the episclera, which forms the superficial aspect of the sclera. The episclera is a thin, dense, vascularized layer of connective tissue, the fibers of which are continuous with the underlying scleral stroma. The episclera blends with the underlying scleral stroma whose fibers become progressively denser and interlaced (Watson 2013).

Beneath this top layer is the substantia propria sclerae (or scleral stroma). This is the thickest layer of the sclera and consists of interwoven collagen fibers. The fibers stabilize the sclera and, consequently, the eyeball. The sclera appears opaque because of the irregular alignment of the fibers. The sclera consists of bundles of flat white collagen fibers crossing parallel to the scleral surface in all directions.

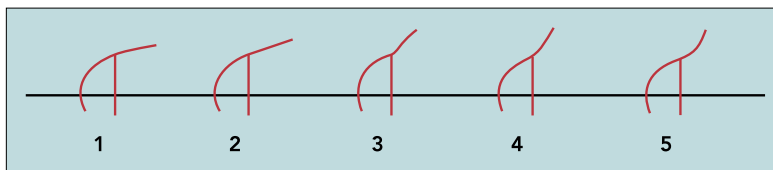
The corneo-scleral junction, or limbus, is the transition zone between the transparent cornea and the opaque sclera. The official transition from cornea to limbus is where Bowman’s layer ends, but the width of the total limbal transition zone is larger: approximately 1.5 mm wide on each side of the cornea in the horizontal plane. The limbal width can be up to 2.0 mm on each side of the cornea vertically. The corneal stromal fibers are irregular in thickness and arrangement, and they change into scleral stromal fibers. So while the five-layer epithelium of the cornea phases into the 10- to 15-layer epithelium of the conjunctiva, Bowman’s layer ends and transitions into the conjunctival stroma and Tenon’s capsule. Epithelial radial “pegs” produce the Palisades of Vogt, which are seen more in the inferior and superior quadrant of the limbus and may be pigmented in darker races. The corneal stroma extends into the scleral stroma.

Corneo-Scleral Junction and Anterior Scleral Shape

To fit scleral lenses, knowledge of the corneo-scleral junction and anterior scleral shape where the scleral lens landing zone rests, seems important. The corneo-scleral junction and the anterior scleral part of beyond the limbus have always been assumed to be curved in shape, but it appears that this is not necessarily always the case. From the molds taken of the anterior segment of human eyes (in normal eyes and in keratoconus), it seems that at least in some cases, the sclera often continues in a straight line (tangential) from the peripheral cornea onward. Also, when using contour maps from the experimental Maastricht Shape Topographer (De Brabander 2002, Van der Worp 2014), one of the first topographers to image the limbus and part of the sclera up to an 18.0 mm diameter of the anterior eye surface (profilometry), it was observed on a case-by-case analysis that the transition is often tangential rather than curved.

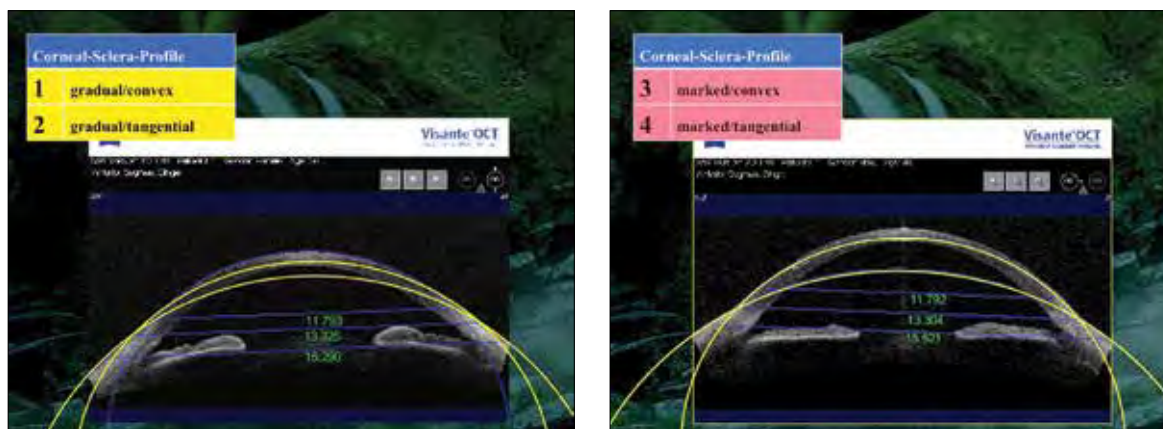
Corneo-Scleral Profile

It is surprising how little is known about the corneo-scleral junction profile, which is a very important parameter when fitting soft and scleral lenses. One of the few mentions of this in the international literature can be found in the German contact lens journal *die Kontaktlinse* (1992). Meier, a Swiss eye care practitioner, defines in this publication different transition profiles from cornea to sclera. He describes five



Different transition profiles from cornea to sclera
Courtesy of Daniel Meier/*die Kontaktlinse*

different models: a gradual transition from cornea to sclera, where the scleral portion is either convex (profile 1) or tangential (profile 2), or a marked transition where again the scleral portion can be either convex (profile 3) or tangential



Corneo-scleral profiles based on OCT images of the anterior eye with a gradual transition (figure on the left) and a marked transition (figure on the right)

Reprinted with permission of *Contact Lens Spectrum*, PentaVision LLC, © 2010, all rights reserved

(profile 4). As a fifth option, he describes a convex corneal shape with a concave scleral shape (profile 5). The profiles in the Meier scale are decreasing in sagittal height, in which profile number 1 has the highest sagittal height and profile number 5 has the lowest sagittal height—an important parameter for fitting scleral lenses.

Studies by Meier, and another study published in *die Kontaktlinse* by Rott-Muff et al (2001), tried to identify how often the different profiles were observed in the general population. The study results were remarkably similar. Profile 2 (gradual-tangential) followed by profile 3 (marked-convex) were respectively the number one and two observed, followed by profile 1 (gradual-convex). Profiles 4 and 5, marked-tangential and convex-concave, were seen minimally, with the latter one almost nonexistent. The question of how accurately these profiles can be subjectively rated by practitioners was also addressed in an article in *die Kontaktlinse* by Bokern et al (2007) a few years later. The authors found a repeatability of only 54 percent using 73 investigators. For some profiles, the repeatability was much lower.

Tangential Shape

Purely based on theoretical considerations, the corneo-scleral junction area would be expected to be concave in shape. But contrary to that general belief, the shape of the transition area between the cornea and sclera appears to be straight in many cases based on OCT measurements at Pacific University. This study involved 96 eyes of 48 normal subjects, and the shape was evaluated in eight different directions on the anterior ocular surface: nasal, nasal-inferior, inferior, inferior-temporal, temporal, temporal-superior, superior, and superior-nasal. The majority of the corneo-scleral junctions exhibited tangential shapes. Only one quarter of cases exhibited concave shapes, and few exhibited convex shapes. In addition, illustrating the individual character of the corneo-scleral junction shape, within one eye different profiles were measured in different meridians.

For the anterior scleral shape (between 15.0 mm and 20.0 mm diameters): in this zone, the shape profile would be expected to be convex; the eye is, after all, an eyeball. But instead, it appears that in most cases the anterior scleral shape is also tangential (e.g. straight), with the expected convex shape a distant second (in less than one-third of the cases), with a minimal number of concave shapes.

The results from the Pacific University Scleral Shape Study seem to indicate several things: practitioners shouldn't assume the corneo-scleral junction area and the anterior sclera to necessarily have the concave/convex shapes that would be expected based on theoretical consideration when fitting/designing a scleral

lens. It is suggested that using tangent angles rather than using curves (or using very flat curves) may be appropriate in many cases when fitting scleral lenses. But large individual differences exist, even within the same eye among various meridians.


Corneo-Scleral Angles and Scleral Angles

Based on the findings described, the Pacific University Scleral Shape Study used angle measurements rather than using curves to further investigate the shape of the corneo-scleral junction and the anterior scleral shape. The corneo-scleral tangential angle between 10.0 mm and 15.0 mm (defined in this study as the limbal angle) as well as the angle from 15.0 mm to 20.0 mm (the scleral angle) was established in 96 eyes of 48 normal subjects using the Visante (Zeiss) anterior segment OCT to develop an eye model for the normal eye. All angle measurements were taken in reference to a horizontal plane: 1,289 angles were thus measured and analyzed in total. A limitation of OCT in its standard modality is that it can measure only up to 16.0 mm of the anterior ocular surface. But if the instrument is slightly decentered, easily up to 20.0 mm and further can be imaged. (van der Worp 2010b/2014, Kojima 2013).


"Purely based on theoretical considerations, the corneo-scleral junction area would be expected to be concave in shape and the anterior scleral shape to be convex (the eye is an eyeball in the end). But contrary to that general belief, the shape of the transition area between cornea and sclera and that of the anterior sclera appears to be straight in many cases based on OCT measurements..."

*Pacific University –
the Scleral Shape Study*

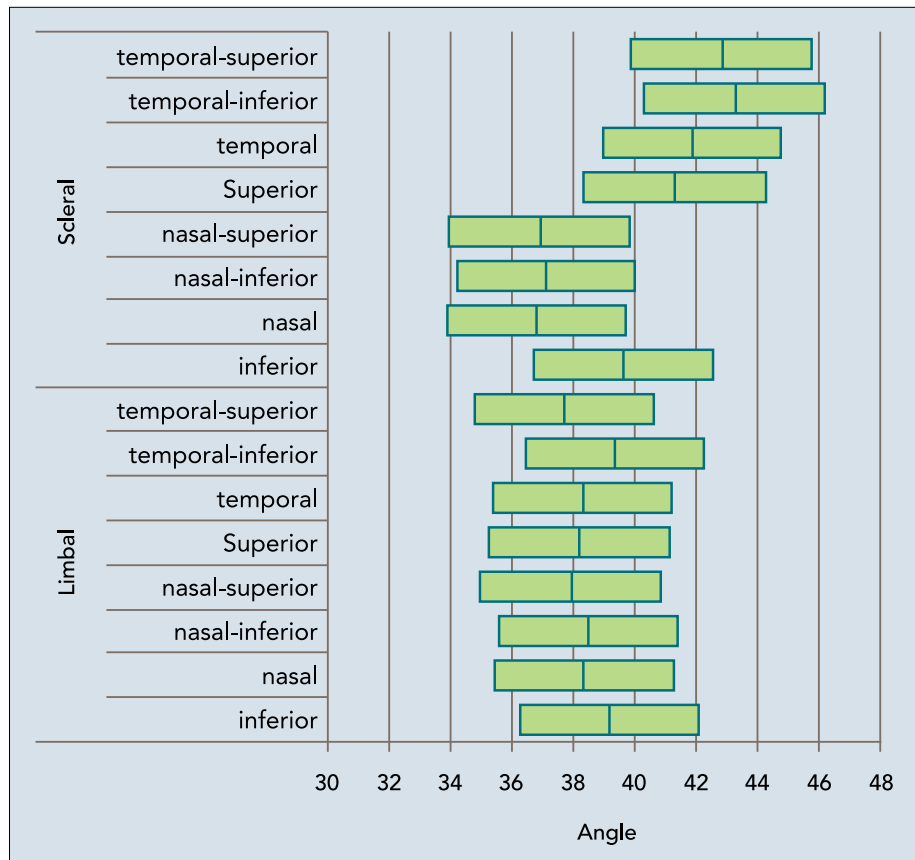
The graph on following page shows the average angles in all sections. From this, it appears first of all that in the average eye, the nasal portion typically is flatter compared to the rest, which is in line with corneal topography findings because the peripheral cornea is typically also flattest in the nasal quadrant. But this effect is smaller in the limbal angles than it is in the scleral angles. Roughly, the limbal angles are in the same range and were not found to be statistically significantly different from each other. But for the scleral angle, especially between the nasal region and the temporal-inferior section, remarkable differences exist. It appears that on the scleral angles, the inferior segment is almost the "benchmark," while the nasal angles are smaller in comparison and the temporal angles are larger, with statistically significant differences between those.



OCT image of steep anterior segment angles: 44.2 and 47.2 degrees respectively for the limbal and scleral angle
(Pacific University – the Scleral Shape Study)



OCT image of flat anterior segment angles: 26.1 and 25.1 degrees respectively for the limbal and scleral angle
(Pacific University – the Scleral Shape Study)



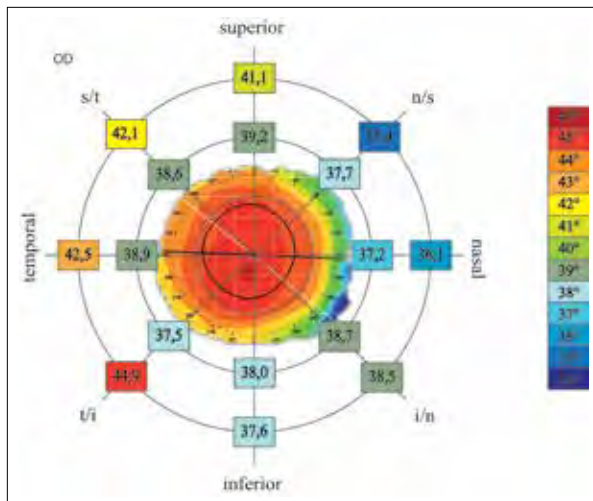
Graph of the average limbal and scleral angle measurements in different meridians—the bars represent the mean (center line) and 84% confidence intervals (Pacific University—the Scleral Shape Study)

Generally speaking, the “model-eye” based on this data looks like this: the inferior segment of the eye typically is “on par” both for the limbal and for the scleral angle. The temporal portion of the anterior ocular surface typically is steeper compared to other areas; the angles are larger in value. The superior segment is somewhat in between the nasal and the temporal in shape, but with a substantial difference between the limbal and the scleral angle.

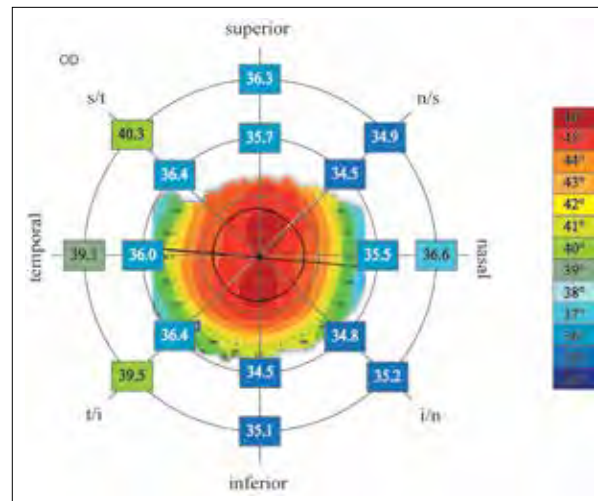
Within the limbal zone, the angle differences are 1.8 degrees on average, although large variations exist among individuals. It is estimated that a 1-degree difference in an average limbal or scleral angle would represent a difference of roughly 60 microns in sagittal height. Based on this, it can be said that in some cases, the difference easily exceeds 540 microns (the thickness of the average normal human cornea) in the limbal zone.

In the scleral zone (15.0 to 20.0 mm), the differences are larger (up to 6.6 degrees on average), but again with large individual differences. Some corneas have more than 1000 microns in difference within one eye, while in others it is limited to 150 microns. Within the limbal area, a 100-micron difference in sagittal height on average can occur between different segments, while this can be close to 400 microns in the scleral zone. Especially for the scleral zone area, this could prove to be highly clinically relevant.

Regarding the asymmetrical scleral shape differences, it appears that corneal astigmatism does not typically extend into the sclera (e.g., a with-the-rule corneal toricity does not necessarily mean there is also with-the-rule scleral toricity). There may be exceptions: clinically, it has been observed that if the corneal toricity is congenital in nature, then this shape may possibly extend into the sclera. No published scientific studies have been found on this topic so far to confirm this.



A typical eye in the Pacific University study—the limbal and scleral angles in eight directions are shown and the corneal topography image is superimposed. The corneal surface is spherical; the limbal and scleral flattening nasally is visible as well as the steepening temporally. (Pacific University—the Scleral Shape Study)



The right eye of a normal subject, the limbal and scleral angles showing a very flat appearance (Pacific University—the Scleral Shape Study)

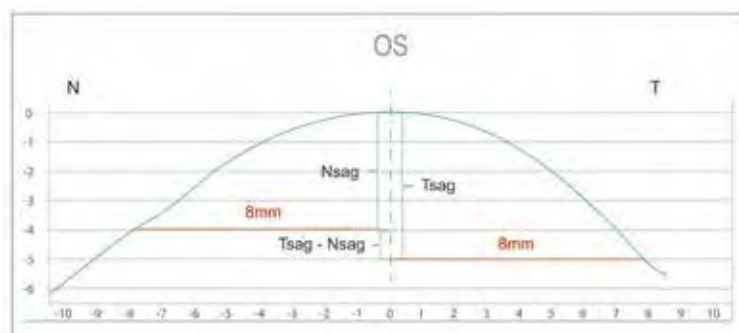
Reprinted with permission of *Contact Lens Spectrum*, Wolters Kluwer Pharma Solutions, Inc., © 2010, all rights reserved

TINA GRAF

Asymmetrical Eye Shapes

Within the limbal zone, the angle differences are on average 1.8 degrees (~100 microns)—in the scleral zone, the differences are much larger, up to 6.6 degrees on average (~ 400 microns); for sure in the scleral area this could be highly clinically relevant.

What these results indicate is that on the average eye, the ocular surface beyond the cornea is non-rotationally symmetrical in nature, or simply said: asymmetrical. It appears that in the average eye, the entire nasal portion typically is flatter compared to the rest. Marriott (1966), a British optometrist, was probably the first to describe this after looking at molds taken from eyes to manufacture haptic lenses. As described in the Pacific studies, it is also evident that this effect (of a flatter nasal appearance) is less for the limbal angles than for the scleral angles. Recently, Hall et al (2011, 2013) published two papers investigating the corneo-scleral junction in normal eyes and found similar results. First, the mean corneo-scleral junction tended to be sharpest at the nasal side (and became progressively flatter at



Difference in nasal appearance (Nsag) versus temporal appearance (Tsag) with the Eye Surface Profiler

the inferior, temporal and superior junctions in their studies), while in many cases they reported that the corneo-scleral junction angles were within 1° of 180°, indicating almost tangential extensions of the peripheral cornea to form the sclera (Tan 2014). Similar findings recently have been reported by Choi et al (2014).

Spiral of Tillaux

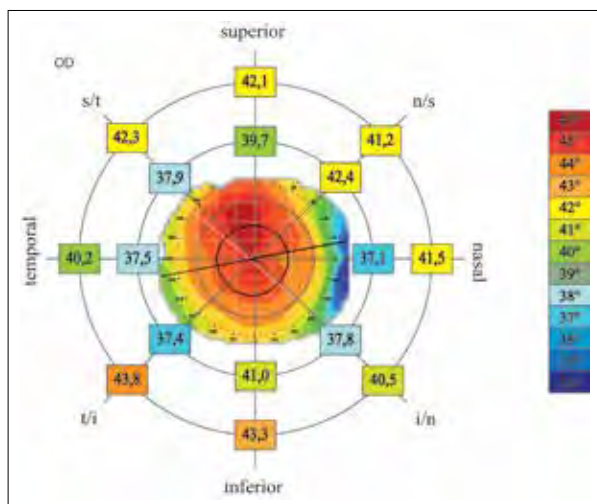
Why the anterior ocular surface has this shape is unclear. A concept introduced at the beginning of this chapter was the spiral of Tillaux, which describes a difference in space between the different rectus eye muscle insertions on the globe and the limbus, when establishing the actual space available in which to fit a scleral lens. It is hypothesized by the Pacific University Scleral Shape Study group that the differences found in scleral shape as described above may be, at least partly, explained by the anatomical features of this spiral of Tillaux. The pattern of increasing space following the spiral of Tillaux happens to be exactly in line with the increase of steepening of the scleral shape.

Clinical Consequences

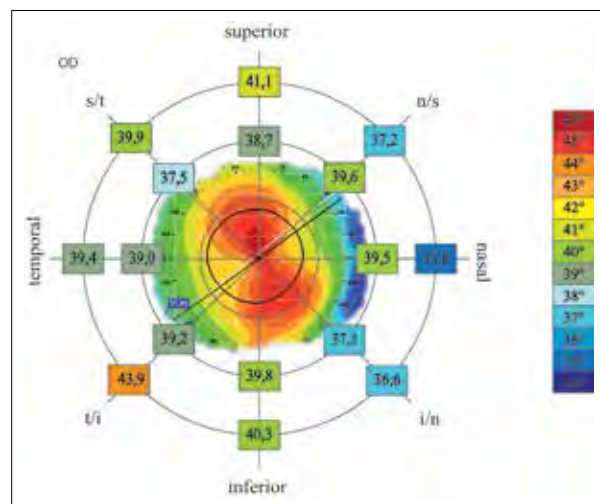
Temporal-inferior decentration of scleral lenses has been described (Caroline 2014b) based on clinical observation in daily practice. Inferior decentration may be the result of eyelid pressure and simply gravity, but the temporal decentration was harder to explain. It appears now that the flatter nasal elevation of the anterior ocular surface beyond the corneal borders plays a role in this. Decentered lenses offset the lens' optics, cause prismatic effects and may result in hard-to-manage differences in limbal clearances nasally and temporally. The asymmetrical shape of the anterior ocular surface has been suggested to also play a role in the phenomenon of loose conjunctival tissue being pulled under the scleral lens. See 'Loose Conjunctival Tissue' item in chapter V for more on this.

Based on the results described above, it appears that for the average eye, asymmetrical lenses such as toric and quadrant specific lenses, both of which are commercially available, could optimally respect the shape of the eye. This is especially the case if the scleral lens diameter goes beyond the 15.0 mm mark. The same effect has been reported based on clinical experience: the asymmetrical nature of the sclera has been noted previously by Visser et al (2006) from clinical experience in using large-scleral lenses. They well described the benefits of using large diameter toric scleral lenses.

In conclusion: in the average eye, the ocular surface beyond the cornea is asymmetrical. It seems that for the average eye, asymmetrical back surface scleral lenses can be beneficial in some cases, more so in the larger



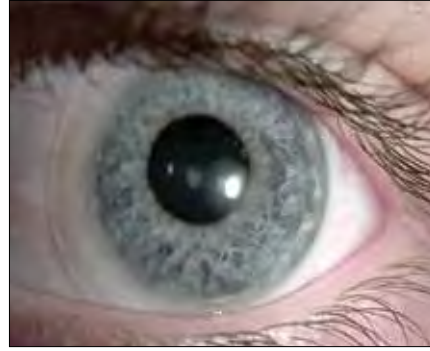The right eye of a normal subject: a rather steep appearance with relative limited differences within both the limbal and the scleral ring (which was not a typical finding in the study) (Pacific University—the Scleral Shape Study)



The right eye of a normal subject with a toric cornea and an asymmetrical ocular surface beyond the corneal borders (Pacific University—the Scleral Shape Study)

TINA GRAF

The results of the Pacific University Scleral Shape Study suggest that the asymmetrical nature of the ocular surface beyond the cornea is in line with clinical experience. In fact, in some practices, asymmetrical lens designs are used more often than not today when fitting scleral lenses.



Bitoric corneo-scleral lens on a toric eye

diameter range. For more complex scleral shapes and/or to follow the anterior ocular surface shape precisely, impression techniques may be a valuable tool (see ‘Impression Technique Scleral Lenses’ section in chapter III). In many practices, asymmetrical lens designs are being more frequently used recently, and in some practices this involves using asymmetrical scleral lenses in the majority of lens fits. See chapter IV, step 5 for a detailed description and coverage of fitting asymmetrical back surface scleral lenses.

Key points:

- *It seems that the shape of the corneo-scleral junction and the anterior sclera is frequently tangential rather than curved.*
 - *Typically in the average anterior eye, the nasal scleral portion is flatter compared to the rest, which may cause temporal scleral lens decentration—especially if the scleral lens diameter goes beyond the 15.0 mm mark.*
 - *Many eyes are asymmetrical in nature beyond the corneal borders. This may call for asymmetrical back surface scleral lenses such as toric and quadrant specific lenses—again, especially in the larger diameter range.*
-

III. Scleral Lens Design

- What is the geometry of a standard scleral lens?
- What advanced scleral lens designs are available?

Scleral lens fitting has evolved from glass blown shells in the late 19th century to today's sophisticated, computer-generated, state-of-the-art and—if desired—custom-made specialty lens devices. Modern scleral lens practices primarily rely on diagnostic scleral lens fitting in which trial lenses are used to select the desired optimal scleral lens. The design of these scleral lenses will be covered in detail here. In the early days of scleral lens fitting, impression techniques were more commonly used, but also in today's scleral lens practice they can prove to have their advantages. Impression technique scleral lenses will be discussed in the second part of this chapter.

Diagnostic Scleral Lenses

Although scleral lens designs by various manufacturers differ to some extent, all scleral lenses in essence share the same basic lens geometry. This section will outline the standard concentric symmetrical lens geometry as well as more advanced lens designs such as asymmetrical back surface scleral lenses and multifocal lens designs. Lens material and lens fenestrations will also be discussed later in this section, as they are both highly relevant to lens design and lens fit.

Spherical Designs

The mother of all contact lenses is the concentric symmetrical, often referred to as spherical, scleral lens. Spherical in this sense relates to the “non-toric” back surface of these lenses. It doesn't indicate anything about the spherical, aspheric or other optical designs on the front surface—hence, the term “concentric symmetrical” may be the most appropriate term, which will be further used here in this guide. The geometry of standard concentric symmetrical scleral lenses can be broken down into three zones:

1. The optical zone
2. The transition zone
3. The landing zone

1. The Optical Zone

The optical zone is the centermost zone of the scleral lens that creates the desired optical effect using radii and lens power. The front surface optics of this zone can be spherical or aspheric. Aspheric anterior scleral lens surfaces, as opposed to spherical front surfaces, may allow for improved optical correction of vision in patients with scleral lenses for corneal ectasia, if the lens centers well (Hussoin 2012). Additionally, higher-order aberration correction on the front surface of the optical zone is also possible in scleral lens wear, especially since scleral lenses are typically very stable on the eye (see chapter IV, section 5).

I start fitting my patients with diagnostic lenses, rather than empirical fitting. It can be intimidating to stray from the parameters outside of the current fitting set when beginning scleral lens fitting. I will order lenses 0.5 mm larger or smaller than my fitting trial lens diameter if desired—but I find that changes greater than 0.5 mm can produce a significantly different fit.

Lynette Johns

As you gain experience with scleral lenses, you may rely on consultants at one lab more than others. Working with consultants gives you less control of parameter decisions, but may bring you to success more quickly.

Stephen Byrnes

This may further improve optical performance, but it should be noted that because of the tear layer behind the lens, standard scleral lenses provide excellent optical quality as corneal irregularities are all neutralized to a very large extent by the tear layer behind the lens.

The back surface shape of the optical zone should ideally have roughly the same shape as the cornea, at least in theory. This way, an even layer of post-lens clearance is created behind the scleral lens' optical zone. To follow the

corneal shape, the back optic zone can be chosen with flatter or steeper radii of curvature. In odd-shaped corneas, such as in keratoconus, for instance, where the cornea is locally protruded, this is not always easy to achieve—and a thinner post-lens clearance will be visible centrally compared to peripherally.

Unlike with corneal GP lenses, the back surface of the scleral lens optical zone usually does not touch the cornea. An exception is when using corneo-scleral lenses, for which manufacturers typically suggest some form of “feather touch” on the apex of the cornea and/or in the limbal area. In the more challenging corneas, such as in advanced keratoconus, full clearance may be desired; this is typically not feasible with corneo-scleral lenses. As long as there is adequate clearance under most of the lens, a good result can be reached, according to corneo-scleral lens experts. It has been suggested that the fluid layer behind the lens may act as a “cushion” in corneo-scleral lenses (Michaud 2013). A larger lens diameter can be chosen to increase the clearance behind the lens, if desired. For further details on this topic, see fitting step 1 and 2 in the next chapter of this guide on choosing lens diameter and creating adequate corneal clearance, which will look at both corneo-scleral and full scleral lenses.

In theory, the same optics rules apply with scleral lenses as with corneal GP lenses: post-lens fluid power changes can be adjusted based on the rule that approximately 0.10 mm of radius change produces a 0.5 D power change. However, this is true for “thin” lens powers, whereas “thick” lens powers would be more appropriate in scleral lenses. Schornack et al (2014) have calculated that if, for example, the lens fit is 6.00 D steep, the “thin” lens power would result in + 6.00 D tear lens power—but the actual “thick” tear lens powers are + 6.61 D for a 200-micron clearance lens and + 7.25 D for a 400-micron clearance lens. In all cases, the actual tear film power is more plus than what would be expected based on initial prediction.

Having said that, for irregular corneas, these theoretical optical rules may often be inaccurate, and the “tear lens” between the cornea and the lens often is not a uniform, optically sound system. The best practice typically is to place a lens on the eye to achieve an acceptable fit, and then perform an over-refraction over that. This would likely be the most simple and efficient method in daily practice. But given the above reasoning, scleral lenses should be fully settled before over-refracting (Chan 2014). If the over-refraction is excessive, this could add another error because of the trial lens vertex distance, and the power needs to be corrected for this: see the ‘over-refraction’ section in chapter IV of this guide.

2. The Transition Zone

A scleral lens has a transition zone between the optical zone and the landing zone that is also referred to as the mid-peripheral, intermediate or limbal zone. It basically connects point A (the location of the end of the optical zone) with point B (the beginning of the landing zone going outward). This zone is important, as it creates the sagittal height of the lens. When trial sets of scleral lenses are based on sagittal height, the next step up (or down) in height translates to an alteration in the transition zone. This is usually done independent of optical zone and landing zone parameters.

A decentered scleral lens will not only decenter the lens optics, it will also displace a large fluid lens on the eye. Low riding scleral lenses will create a base-down prismatic effect. The displacement of the centre of curvature from the visual axis (in centimeters) multiplied by the power of the surface will determine the prism power due to anterior displacement. Prismatic effects of any contact lens fitted on or near alignment will be small.

Douthwaite 2006

For large diameter scleral lenses, the transition zone keeps the back surface of the lens clear of the cornea and the limbus. The transition zone geometry as such is not the most critical part of the lens for large diameter designs. Oftentimes, splines or more sophisticated lens logarithms are used to define this zone (Rosenthal 2009b), which explains some of the differences among the various lens designs. Alternatively, this zone consists of a series of peripheral curves or angles extending out into the landing zone area. The transition zone may also be

designed in a reverse geometry profile, resembling orthokeratology lens designs, to accommodate special corneal profiles that are sometimes present after, for instance, refractive surgery procedures (LASIK, LASEK or PRK) or after penetrating keratoplasties.

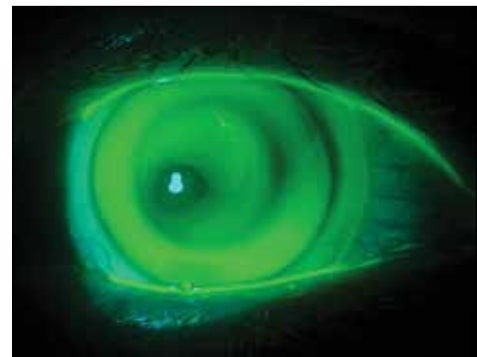
With smaller size scleral lenses, specifically corneo-scleral lenses, it is important to consider the shape of the transition zone and to make sure it is in line with the corneo-scleral junction shape to minimize mechanical pressure in that area, since limbal clearance is typically minimal or not present at all with these lenses because it is where the lens rests. The shape of the transition zone can be adjusted with some lens designs, in which different profiles are available to the eye care practitioner to optimally respect the corneo-scleral junction shape. Other lens designs use a series of peripheral curves to adjust this zone.

3. The Landing Zone

The area of the lens that rests on (and tries to mimic the shape of) the anterior ocular surface is called the landing zone. This is where the lens actually “fits” and makes contact with the ocular surface; it is therefore crucial in terms of scleral lens fitting. With full scleral lens diameters, the landing zone also is sometimes referred to as the scleral zone or haptic zone. The word haptic is derived from a Greek word meaning “to fasten” or “to attach.”

It is important that the shape of the landing zone aligns with the scleral profile when fitting full scleral lenses, and that it aligns with the corneo-scleral junction profile when fitting corneo-scleral lenses. It is key to evenly distribute pressure over the entire landing zone area so as to distribute the pressure of the lens over a maximum possible surface area. When the pressure is evenly distributed in this way in full scleral lens fitting, a complete corneal vault consequently can be achieved, thus creating adequate corneal clearance.

Typically, the landing zone of a full scleral lens is defined as a flat curve or a tangential angle, or series of either, extending out from the transition zone; this shape can normally fit the majority of eyes (Pullum 2007). The landing zone area can be modified by using flatter or steeper radii of curvature, or by altering the landing zone angle. Because both clinical experience and recent studies have shown that the anterior eye is tangential in shape rather than curved in many cases (see chapter II of this guide), some companies have developed tangential landing zone designs. These lenses use “opening angles” (e.g., straight lines) rather than curves to influence the landing zone fit. Altering the opening angle can steepen or flatten the landing



Light touch with corneo-scleral lens in a keratoconus eye

SOPHIE TAYLOR-WEST

zone fit. Alternatively, and maybe somewhat confusingly, some tangential lens designs have a curved landing zone; when altering the landing zone of such designs, the curve itself is kept constant, and angles are used to flatten or steepen the landing zone area (as opposed to changing the curvature of the landing zone).

Toric Lens Designs

More recently, the availability of specialized scleral lens designs has expanded considerably. Practitioners now have access to a variety of toric lens designs, with a choice of front, back or bitoric scleral lenses. This section will first discuss back toric lenses, followed by front surface toric lens options. The latter are used to improve visual performance, and the toric portion is positioned on the front surface of the central optical zone of the lens. For back toric scleral lenses, it is the landing zone (or haptic zone) area that is made toric to improve lens fit, and this does not interfere with the central zone of the scleral lens.

A bitoric scleral lens design combines the fitting characteristics of the back toric lens geometry (on the landing zone) with the optical benefits on the front surface of the scleral lens (in the central optical zone).

As discussed earlier in this guide, the anterior ocular surface appears to be asymmetrical in shape, at least to some degree, in most eyes. Asymmetrical back surface scleral lenses such as toric or quadrant specific lenses can lead to better ocular health because fewer areas of localized pressure are created, which can result in reduced conjunctival blanching (a term used to describe a decrease in local conjunctival blood supply, see step 3 of chapter IV) and decreased bubble formation; such designs can also prevent excessive tear exchange plus debris inflow. Practitioners using the corneo-scleral lens designs typically report that they less frequently need asymmetrical back surface designs compared to practitioners using larger diameter

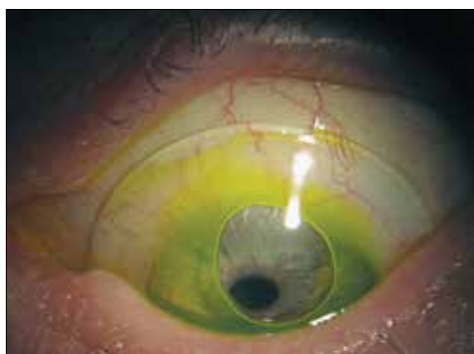scleral lenses—which is in line with the Pacific University Scleral Lens Shape Study results. Still, even with smaller lens designs, a number of lens fits may fail or may be suboptimal because of a tight lens-to-ocular surface relationship in one or more quadrants, resulting in localized mechanical pressure and possibly conjunctival staining—or resulting in a gap between lens and sclera, potentially leading to unwanted bubble formation. In these cases, an asymmetrical back surface scleral lens would be indicated. With larger scleral lens diameters, the asymmetrical nature of the sclera becomes more prominent, urging the need for such lenses more frequently. Generally, it is believed that the further the lens' landing zone goes out across the limbus (e.g., the larger the scleral lens diameter is), the higher the demand for an asymmetrical back surface scleral lens. This may at least in part explain the large variation among practices: some practices report almost exclusively using asymmetrical back surface scleral lenses, while many others hardly use any of them, and many lens designs do not even offer the option.

One step up from this, which seems to be supported by the data on scleral shape as described in chapter II, is to upgrade

The landing zone area should be at least 3 mm wide to provide comfortable lens wear. More comfort is typically reached by increasing the landing zone diameter.

*Esther-Simone Visser
and Rients Visser*

The landing zone, also called the haptic zone, is where the lens actually “fits” and makes contact with the eye. The word haptic is derived from a Greek word meaning “to fasten” or “to attach.”



Quadrant specific lift of a standard, concentric symmetrical scleral lens on an asymmetrical sclera

to quadrant specific lens designs. Because the sclera does not appear to be symmetrical in shape in a specific pattern of meridians ninety degrees apart, this could be a valuable next step in the evolution of scleral lenses. A limited number of manufacturers are currently successfully manufacturing quadrant specific scleral lenses. The fitting of these lenses is mostly done based on clinical experience and trial and error, primarily by looking at localized areas of pressure or lift of the scleral lens' landing zone as well as by conjunctival observations upon removal. See chapter IV step 5 for more details.

Visser (2006, 2013) and others (Schornack 2013) clearly emphasized the advantages of back toric scleral lenses, and Gemoules (2008) presented a fitting technique using the Zeiss Visante® OCT to optimize the fit. These studies boast longer wearing time and better comfort in well-fitted back surface designs with these asymmetrical geometries in the landing zone area.

Because asymmetrical lenses more precisely follow the shape of the anterior eye beyond the cornea, they are exceptionally stable on the eye. In a study by Visser (2006), it took six seconds on average for back toric scleral lenses to return to their initial position after the lenses were manually rotated to a different position. In a recent study by Visser (2013), using a different bitoric scleral lens design, it was remarkable to see that the median stabilization axis of the scleral lenses used were very similar to those previously reported. In the new study, the median in the right eyes was 140° (range 0-180°) compared to 137° (range 30-180°) in the earlier study; in the left eyes it was 60° (range 0-180°) compared to 47° (range 0-170°) in the previous study. This opens up the possibility for additional optical corrections such as front cylinders, but also for correcting higher-order aberrations such as, for instance, vertical coma, which is a frequent finding in keratoconus

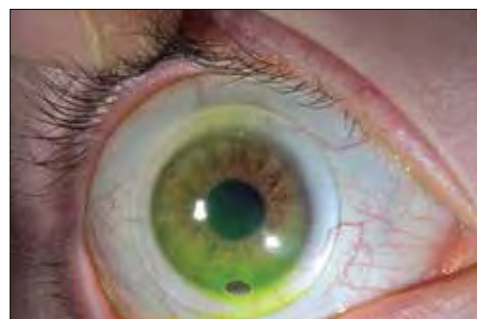
(Sabesan 2013). This can help further improve visual performance in these patients, although there may be an adaptive component where the patient has to get used to the “new optics.” In other words: the human brain may not immediately entirely appreciate the full effect of the superb optical quality that these lenses can provide.

The advantages of back toric scleral lenses seem evident; longer wearing time and better comfort in well-fitted back surface designs have been described—especially for larger diameter scleral lenses.

See chapter IV, step 5, for a more detailed description of the fitting details regarding these kinds of lenses. Impression technique scleral lenses may offer the same, or improved, advantages to that which back

toric and quadrant specific lenses can offer. See ‘Impression Technique Scleral Lenses’ next in this chapter.

Front toric scleral lenses are quite rare, but they are indicated when a residual cylinder over-refraction is found and there is no indication to fit a toric back surface design lens. Therefore, this lens needs its stabilization in another way than from the asymmetrical back surface. A limited number of newer scleral lens designs have dynamic stabilization zones (thicker and thinner areas) or prism ballast built into the lens. This will allow for the lens to stay fixed on the eye by gravity and eyelid forces. The desired front cylinder can then be added to the front surface of the lens to achieve the best optical outcome using the LARS rule (see ‘Fitting Toric Scleral Lenses’ in chapter IV). Some practitioners, however, prefer to simply prescribe glasses with a prescription matching the cylinder over-refraction, to be worn as desired by the patient over the scleral lens—for instance, while driving a car.



Standard, concentric symmetrical scleral lens on an asymmetrical sclera

©Universitair ziekenhuis Antwerpen

JAN PAUWELS

The advantages of back toric scleral lenses seem evident; longer wearing time and better comfort in well-fitted back surface designs have been described—especially for larger diameter scleral lenses.

Multifocal Contact Lens Designs

Also fairly recently, different multifocal scleral lenses have entered the market. These are likely more suitable for patients with nonpathological eyes, but combinations should not be excluded up front. To speak in the words of some experienced scleral lens fitters: “keratoconus patients age, too, and consequently develop presbyopia as well.” The design of these lenses would fall into the “simultaneous multifocal lens design” group (aspheric or concentric), in which two images with different focal points are presented at the same time to the eye (e.g., simultaneously). Both center-near and center-distance geometries are available, typically in the smaller scleral lens diameter range. With larger diameters and typically larger amounts of clearance, the optics calculation becomes more complex and less predictable due to the vault and lens decentration effects.

The major advantage that the available scleral multifocal lenses have over corneal GP multifocal simultaneous lenses is that they are very stable on-eye, and the concentric zones can be matched more precisely within the desired pupil diameter zone compared with lenses that move, often quite excessively, over the ocular surface. To some degree, scleral lenses may have an advantage even compared to multifocal soft lenses, as the optical quality of GP materials is superior to that of soft lenses, masking all corneal irregularities and increasing contrast sensitivity.

Lens Material

Scleral lens material has evolved from PMMA, with a diffusion coefficient (Dk) of zero, to the currently available high- and ultra-high-Dk lens materials, as are used for corneal GP lens wear.

Scleral lenses are made out of special buttons (blanks) with a diameter of up to 26 mm. Compared to corneal GP lenses, scleral lenses are considerably thicker—typically in the 0.25 to 0.4 mm thickness range, but they can be much thicker in some large diameter full-scleral lenses. This thickness can have a dramatic effect on the oxygen transmissibility (or Dk/t) of the lenses, as this is calculated based on the oxygen permeability of the material (Dk) in conjunction with the lens thickness (t). A thicker lens, therefore, by definition would have a lower Dk/t. It should be kept in mind, in this regard, that the thickness of a scleral lens tends to increase towards the periphery—while typically central thicknesses are reported and discussed.

In addition, an extra layer is added to the lens-to-cornea system: a relatively thick tear layer. The Dk of this tear layer is believed to be 99 (Compañ 2014). This added layer would therefore be an extra “filter” with a potential influence on the Dk/t of the system, the magnitude of which would depend on its thickness.

Increasing oxygen transmissibility of a scleral lens, therefore, can be accomplished in one of three ways: 1) choose the maximum Dk for the GP scleral lens material, 2) reduce the tear clearance behind the lens, and 3) reduce center thickness of the scleral lens itself (Michaud 2012). Details of the exact recommendations can be found in the ‘Hypoxia and Edema’ section in chapter V.

Making the lens thinner to increase oxygen supply through the lens is not always an option, though, as the thickness of a scleral lens needs to be sufficient to prevent lens warpage. Thin scleral lenses have the tendency to quickly warp, either on-eye because of the asymmetrical nature of the anterior surface, or ex vivo due to lens handling and

Due to difficulty in cleaning of the back surface of scleral lenses, lens comfort can degrade with time due to back surface deposition.

Jason Jedlicka

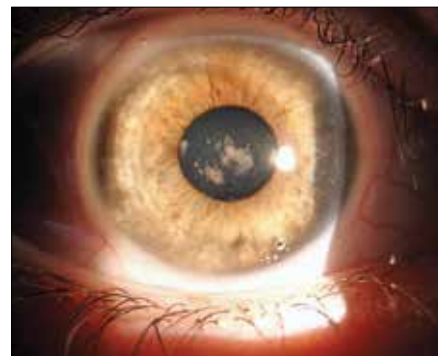


Buttons in various diameters

manual cleaning. Keratometry or topography over the scleral lens can be helpful in detecting lens flexure. For concentric symmetrical scleral lenses, the anterior surface should be spherical: if the overkeratometry values indicate a cylinder, the lens is warped, which may cause vision problems. Replacing the lens and potentially increasing its central thickness may solve the problem. Switching to a back surface asymmetrical lens design (such as a toric back surface design) also may be indicated. See chapter V for more on this topic.

Tear flow beneath contact lenses can also bring in oxygen-rich tears to supplement the oxygen demand of the cornea, as is the case in corneal GP lens wear, but the tear film replenishment under scleral lenses is minimal if not absent. It appears, therefore, that the cornea is highly dependent on the oxygen transmissibility through the scleral lens. Because the lens typically vaults the limbus in scleral lenses, oxygen from the conjunctival and limbal vessels in theory may contribute to the oxygen supply to the fluid layer, and thus to the cornea. Some practitioners contend that fitting fenestrated lenses may add to oxygen delivery to the eye, although the full effect of fenestrations on oxygen supply is unclear at this point.

Many scleral lenses are plasma treated to improve wettability, which seems to be the preferred option. The replacement schedule of scleral lenses varies widely, from a standard one-year replacement regimen to optional/on-demand lens replacement in which the lens can last for several years. Some practitioners report that after several months of lens wear, presumably in part because the plasma treatment wears off, wettability decreases and comfort degrades. Also, it is not always easy to adequately clean the inside of the scleral lens bowl—hence, more frequent replacement may be a good option.



SOPHIE TAYLOR-WEST

Heavy protein buildup on a scleral lens

Fenestrations can sometimes allow bubble formation, but can also, on occasion, allow bubbles to escape—especially in smaller type scleral lenses.

Jason Jedlicka

Fenestrations

In the “PMMA scleral lens era”, fenestrations or channels were commonly incorporated because they were thought to provide circulation of fresh oxygenated tears. But modern scleral lenses are all gas permeable, and oxygen delivery is not the most important consideration for fenestrations anymore. In fact, it is still under debate as to what degree fenestrations are beneficial to the oxygen delivery effect to the cornea.

Whether fenestrations are beneficial or not, in general, has been a point of discussion in the scleral lens field. It has been suggested that, in theory, more “suction” of the lens can occur in nonfenestrated lenses, and that fenestrated lenses are easier to remove and can improve the exchange of metabolic debris, but no scientific evidence for these theories is available.

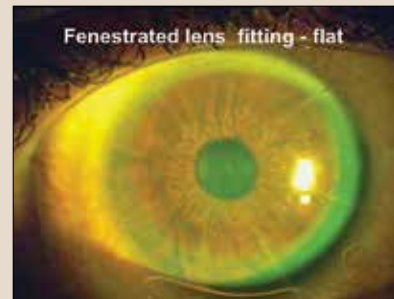
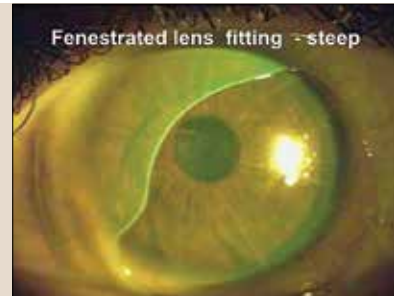
Fitting fenestrated lenses is significantly different from fitting nonfenestrated lenses. Nonfenestrated lenses float more on the eye, while fenestrated lenses “sink” more into the anterior ocular surface. Typically, the clearance in fenestrated lenses is much lower than in nonfenestrated lenses. If the preferred typical clearance is in the 200- to 300-micron range with nonfenestrated lenses, with fenestrated lenses this can be less than 100 microns with the same lens design and diameter. This may be an advantage for keeping the clearance area air-bubble free, but fenestrations can actually also cause air bubbles in the area of the fenestration. In smaller scleral lens designs, a fenestration hole may be beneficial in relieving negative pressure. It should also be kept in mind that lens solution and debris, as well as potentially microorganisms, may accumulate in the fenestrations because the fenestrations holes cannot be manually cleaned.

Fenestrated Lenses

There is a general belief that fenestrated lenses are difficult to fit, as these lenses tend to settle on the eye. But it is not difficult to estimate this effect and to compensate to allow for this in the initial lens ordered. In our opinion, there are a number of advantages of a fenestrated lens over a sealed lens:

- 1. Having a fenestration in the lens promotes renewal of flow of tears over the cornea and may help remove waste products from under the lens.*
- 2. Fenestrated lenses are inserted without the need to have a solution in the lens bowl. This makes the placement and removal of the lens quite straightforward, especially with pediatric patients.*

Don Ezekiel



DON EZEKIEL

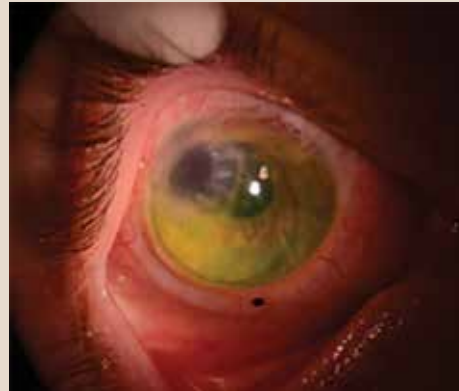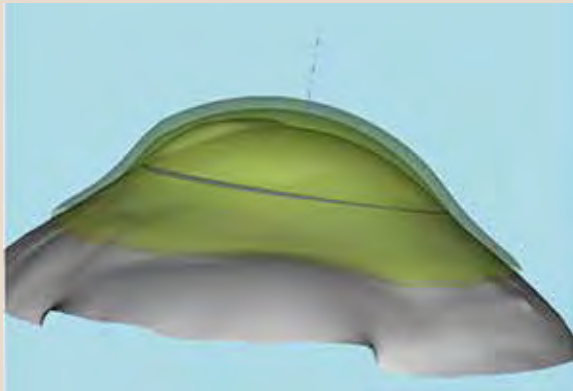
If fenestrations are used, the fenestration holes should be roughly 0.5 mm to 1.0 mm in size and placed in the deepest pooling area over the limbus (DePaolis 2009). If the fenestration hole is obscured on the inside by corneal or conjunctival tissue, it will have no effect. In some cases of loose conjunctiva (as in conjunctival chalasis), the negative pressure under the lens can be such that the conjunctiva can be sucked under the lens and even through the hole.

Impression Technique Scleral Lenses

Although not very commonly used in most contact lens practices today, impression techniques have been utilized successfully for many years (Pullum 2007) and may see a revival in coming years. The original technique that was used consists of an impression that is created of the anterior ocular surface. Specialized equipment is needed to perform this procedure, whereby local anesthetics usually are required. Of this impression, a negative mold is created. Typically dental material, or an alternative, is used in recreating the anterior ocular surface shape. This cast can be sent to a specialized manufacturer to produce a scleral lens device. These lenses follow the shape of the anterior surface precisely, and the cast retains its shape for many years so the lens can be reproduced at a later time. In the hands of a specialized fitter, this technique can still have added value.

In the past, though, ocular plaster molding techniques have been described as invasive, messy and time consuming. But the biggest downside of the method was that heat was required in manufacturing the lens, which basically limited this technique to PMMA materials. Recently, however, an updated version of molding, using

The Boston Foundation for Sight has established special terminology for their treatment model for complex corneal disease using scleral lens devices. PROSE stands for "prosthetic replacement of the ocular surface ecosystem." PROSE treatment uses FDA approved (1994) scleral lens prosthetic devices to replace or support impaired ocular surface function in cases of "distorted corneal surface or certain ocular surface disorders." PROSE treatment has proven to be very successful and is the subject of many peer-reviewed articles in the international literature.



This patient has Terrien's marginal degeneration. The image (left) shows the cast of the eye with a virtual scleral lens design superimposed. Eyes like this are virtually impossible to fit with any other design because of the vast differences in elevation. This patient sees 20/20 with this impression technique scleral lens (picture right) that was thus designed and manufactured.

- Christine Sindt

a special type of polyvinyl siloxane polymer, has re-entered the market. It is a relatively fast procedure that does not hurt the eye. The mold is then digitized, and this file can then be used to create a state-of-the-art, customized lathe-cut scleral lens device (Woo 2014a, Sindt 2013). These lenses can then be made in any material possible and in any lens thickness, and they are very reproducible because the digital data remains on file. Some special training is required to use this technique.

The fact that these impression scleral lenses closely follow the shape of the anterior eye has been described as an advantage (as reported earlier in this chapter). Another advantage of the system is that the practitioner does not need an expensive fitting set. There also is a need to perform impression molding in cases of markedly disfigured eyes or for custom-fitted ocular prostheses.

Key points:

- *Scleral lenses basically consist of three zones: the optical, transition and landing zones.*
 - *Asymmetric, front toric and multifocal scleral lenses are available and could be highly beneficial to some patients.*
 - *Modern scleral lens fitting relies almost exclusively on diagnostic scleral lenses, but impression technique scleral lenses can have added value in some cases as they follow the shape of the anterior ocular surface closely.*
-

IV. Fitting Scleral Lenses—a Five Step Fitting Approach

- What parameters to consider when fitting scleral lenses
- How to follow a five-step fitting approach for general scleral lens fitting

In the past, one of the major disadvantages of fitting scleral lenses has always been the time, skill and expense required to fit them. This has dramatically changed over recent years as a result of improved knowledge about the ocular surface and new design possibilities as well as improved materials to work with. The five-step fitting approach presented here is for diagnostic scleral lenses and is a general fitting guide to explain the essence of scleral lens fitting for the different types of scleral lenses available today. Different rules may apply for specific types of lenses. The order of the five steps is almost arbitrary: many practitioners, for instance, prefer to work from the periphery back to the center, which would be the opposite of the way most standard corneal GP lenses are fitted.

Scleral lenses are primarily fitted based on sagittal depth; keratometric readings are of relatively limited use. Two eyes with the same keratometric values can have totally different sagittal heights. The average total sagittal height of the fitted area of a normal eye (over a 15.0 mm chord) typically is in the $3,740 \pm \text{SD } 200$ micron range (Achong 2012, Sorbara 2010). Sagittal height is dependent on a number of variables including lens diameter, radius of curvature, asphericity of the cornea, and the shape of the anterior sclera. The inability to measure the latter up to now had made calculation of the sagittal height virtually impossible in clinical practice. However, with advanced topographical technology such as the OCT and, more recently, profilometry (see chapter II of this guide), the total sagittal height of the anterior eye can be measured and potentially matched by scleral lenses of the same sagittal height. But most eye care practitioners today use fitting sets, in which the anterior surface topography can be diagnostically met in a clinically proven, successful way.

This chapter focuses on the individual steps needed to fit scleral lenses, independent of manufacturer and design.

Step 1: Diameter

- How to choose the overall scleral lens diameter
- How to assess and evaluate the optical/clearance zone diameter

Total Diameter

The total lens diameter is the first and most basic consideration for eye care practitioners in the scleral lens fitting process. This decision is a subject of discussion within the scleral contact lens field, in which individual practitioner preference, regional and national differences and even cultural characteristics play an important role. But there are also a number of independent variables to consider.

In this five-step fitting approach for diagnostic scleral lenses, the total lens diameter and optical zone diameter are the first points to consider (step 1), followed by establishing the central and limbal clearance (step 2), the appropriate landing zone alignment (step 3), adequate lens edge lift (step 4) and finally the asymmetrical design of the lens (step 5).

In favor of larger diameter lenses is the amount of tear fluid reservoir that can be created. Typically, the more clearance required, the larger the lens diameter should be. This means that for a fragile corneal epithelium, a larger lens may be required to completely clear the cornea. Larger diameter lenses are also typically suggested for large sagittal height differences on the cornea, such as in corneal ectasia. With bigger lenses, a much larger area of bearing is created in the landing zone, which prevents local areas of excessive pressure and may improve comfort of wear. Mini-scleral lenses may potentially “sink” more into the conjunctiva.

The case for the smaller diameter scleral lenses, such as corneo-sclerals, is that they may be easier to handle, may not need to be filled with fluid upon lens placement and will cause fewer air bubbles under the lens. They also may be prone to have more mobility on the eye. For more normally shaped corneas and for noncompromised eyes, this may be a valid option. Because the clearance is smaller than with larger diameter scleral lenses, visual acuity is typically good with these lenses. Another advantage seems to be that smaller diameter lenses tend to avoid problems resulting from the scleral toricity, as this increases toward the periphery (see chapter II). Also, these lenses tend to be somewhat less expensive than large diameter scleral lenses in general.

Large lens diameters may tend to decenter more, typically in the temporal direction due to the flatter nasal shape of the eyeball in many cases. If large scleral lenses decenter, switching to a smaller diameter may solve the problem. Alternatively, the decentration caused by nasal pressure may also be alleviated with an asymmetrical scleral lens (see step 5 of this chapter).

It seems there is certainly a place for both large and small diameter scleral lenses. The diameter choice can actually be arbitrary, as an acceptable fit may be reached with a 15.0 mm lens or with a 23.0 mm lens on the same patient (Jedlicka 2010b). Many companies offer different diameter options within their lens designs.

Small increments in lens diameter can have dramatic effects on surface coverage area. Increasing lens diameter from 14.0 mm to 15.0 mm results in an increase in total surface area of the circle under the lens from 154 mm² to 177 mm²: an increase of 23 mm². With larger lenses this effect is even greater: from 314 mm² in a 20.0 mm lens to 346 mm² in a 21.0 mm diameter lens (a difference of 32 mm²).

Some lens designs limit practitioners to one lens diameter; adding another lens design that has a different total lens diameter to the arsenal may be advised to deal with all challenges of the scleral lens practice.

Optical/Clearance Zone Diameter

Within the diameter consideration of the scleral lens fitting process, it is important to also discuss the optical zone diameter. The optical zone diameter contributes to providing a good optical outcome; therefore, it should not interfere with

the pupil diameter, taking into account the depth of the anterior chamber including lens clearance. When determining optical zone diameter size, it should also be taken into account that scleral lenses can somewhat decenter. However, although theoretically this is a critical consideration, many scleral lens designs have fixed optical zone diameters, so it may not always be possible to change this parameter within one lens design.

Total corneal vaulting is the objective, and even limbal clearance is desired with many scleral lenses, so determining an adequate optical zone diameter is crucial. Corneal diameter can be used as a guideline and starting point. Although large variations may exist, the clearance zone area, consisting of the optical and the transition zone of the scleral lens (which is often fixed in diameter) is often chosen roughly 0.2 mm larger than the corneal diameter.

If the optical and transition zones are fixed in diameter, this parameter can be checked on-eye to assess whether the zone diameter is adequate. Switch to an alternative lens design if it is not desirable. The size of the optical zone diameter itself depends on the lens design used. It should cover the pupil zone fully to prevent any optical disturbances. As said: often the optical zone diameter is set, and not all lens designs allow for alterations of this parameter. Switching to a larger overall lens diameter may be a valid alternative.

Step 2: Clearance

- How to define corneal clearance
- How to define limbal clearance

It can be difficult to apply full scleral lenses on small children because of the necessity of filling the lens and the inability of little children to sit still in a face-down position; therefore, sometimes the vault needs to be decreased. However, it is possible, and children do get better at application as they get older.

Christine Sindt

Corneal Clearance

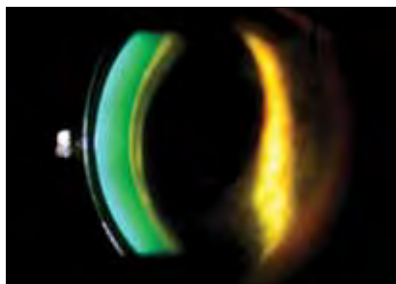
The next step is to define the amount of central corneal clearance. Corneal clearance is probably the single most important advantage that scleral lenses have over corneal lenses, and it seems advised to take advantage of that. Up to 600 microns of corneal clearance can be achieved if desired, although this is considered excessive. The preferred terminology in evaluating clearance is an “increase or decrease” in sagittal height—hence, using microns as the main metric. Many lens designs exclusively define their trial lenses in terms of sagittal height. Increasing the sagittal height of the lens causes the lens to “lift” off the cornea, increasing the clearance or vault of the lens. The terms “flat” and “steep” are best avoided when referring to the increase or decrease in clearance (although, confusingly perhaps—steepening a lens base curve increases the sagittal depth, and flattening a base curve decreases the sagittal depth of a lens).

Scleral lenses need time to settle as they can “sink” into the conjunctiva to some degree, but this is subject to a high individual variance. It is recommended to wait about 20–30 minutes before evaluating the lens on the eye. It is estimated that various lenses can sink considerably, probably in the 100-200 micron range. Most of the sinking takes place in the first two hours of lens wear, but the best time to evaluate the overall sinking would be at the end of the day after eight hours or more of lens wear. Hence, when fitting scleral lenses, an extra margin in terms of clearance should be built in at the beginning. Starting off with slightly excessive clearance is advised to allow plenty of space for the lens to settle.

Corneal clearance is probably the single most important advantage that scleral lenses can offer over corneal lenses.

Amount of Central Corneal Clearance

There are no “rules” for the exact amount of central corneal clearance, but typically a minimum of 100 microns seems desired, although in corneo-scleral lenses there may be much smaller clearances. With full scleral lenses, a clearance of 200–300 microns is usually considered sufficient, but this can go up to 500 microns if desired in exceptional cases with the larger diameter lenses. Mini-scleral lenses are positioned in between corneo-scleral and large-scleral lenses with regard to level of clearance.



GREG DENAEYER

As an illustration, an 18 mm lens holding a 1600 micron tear reservoir

To assess the shape of the anterior ocular surface, we try to grade the total sagittal height as either shallow, normal deep or very deep, and based on this the first trial lens is decided on.

*Esther-Simone Visser and
Rients Visser*

For comparison, and as a reference when evaluating the clearance on-eye, the average corneal thickness of a normal eye is in the 530-micron range centrally, with values up to the 650-micron range in the periphery (Doughty 2000) near the limbus. In conditions such as keratoconus, this can be significantly less. If central scleral lens thickness is known, this may be a better reference point—especially when fitting ectatic corneas since the corneal thickness in these eyes is unpredictable. Manufacturers will usually provide the center thickness information of their (trial) lenses, which could serve as the best benchmark in evaluating corneal clearance.

The desired sagittal depth differs with the condition—e.g., a keratoconus patient typically needs a different (larger) total sagittal lens height than a normal shaped eye. Adding another 100 microns of clearance or so may prove to be useful in keratoconus eyes, to account for potential progression of the ectasia in the future.

In managing ocular surface disease, scleral lens specialists sometimes indicate that larger sagittal heights are preferred to create a full moist layer between the lens and the cornea. On the other hand, to prevent debris build up and potential fogging (see chapter V, ‘Fogging’), lowering the clearance may be desired in these cases. Some companies offer different fitting sets for different conditions (ranging from post-

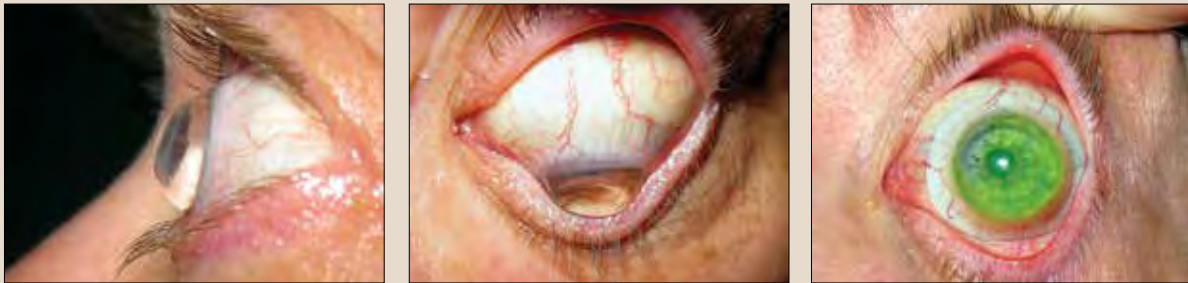LASIK, post-RK and post-corneal graft to normal eyes and ectasia). This may make finding the optimal lens clearance easier. Some companies use keratometric values to estimate the sagittal height of the first trial lens to be applied to the eye: for very steep corneas, the highest sagittal heights are advised (as in keratoconus), while for very flat corneas (typically post-corneal graft and post-refractive surgery), the lowest sagittal height lenses are advised as a first step in the trial lens procedure.

Evaluation of Central Corneal Clearance

It is advised to start with a lower sagittal height lens for a particular cornea and then gradually try diagnostic lenses with more sagittal height until the lens no longer shows apical touch on the cornea, or it shows a “feather touch” as with corneo-scleral lenses, as will be discussed later in this chapter. Or the reverse can be employed: start with an increased sagittal height and gradually go lower.

Increasing the sagittal height of the lens causes the lens to “lift” off the cornea, increasing the clearance or vault of the lens. The terms “flat” and “steep” are best avoided when referring to the increase or decrease in clearance.

Because the clearance retains a fluid-filled reservoir, it is advised to fill nonfenestrated scleral lens with nonpreserved saline upon lens placement to avoid air bubbles. With corneo-scleral lenses this may not be required, although for truly irregular corneas this still may be needed. Fluorescein should be added at this point to the fluid filled lens before placing it on the eye. Tear film exchange is limited once the lens is placed on the eye: this may be more true for full scleral lenses than for corneo-scleral lenses. A green, even fluorescein pattern should be visible in front view, preferably without bearing zones. The human eye is capable of observing 20 microns or more of fluorescein layer thickness. Anything less will appear black, but this doesn’t necessarily mean there is actually “touch,” as the human eye is not capable of seeing fluorescein layers with a thickness shy of roughly 20 microns. Lens decentration can be easily observed in this way as well. But if corneal bearing is visible in larger diameter scleral lenses, the sagittal height of the



GREG DENAEYER

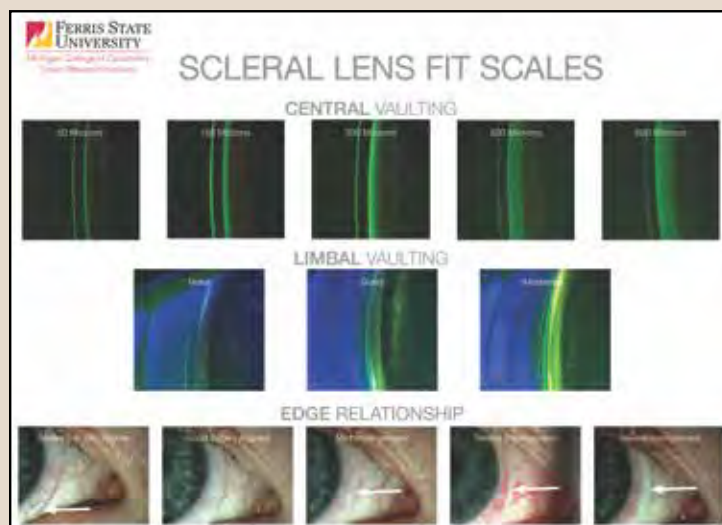
Patients with keratoglobus can be challenging to fit. Since the whole cornea is protruded, scleral lenses that have larger than normal optic zones and large sagittal heights are often needed to vault these extreme corneas. A reverse geometry design may allow for more lift to improve overall clearance. Above is a patient with recurrent keratoglobus 15 years after a PK. The total sagittal depth of this lens is over 8,000 microns.

– Greg DeNaeyer

lens is generally believed to be too low. Typically, the larger the area of central bearing, the more the sagittal height needs to be increased. On the other hand, air bubbles beneath the lens (if not caused by incorrect lens placement) can be a sign of excessive corneal clearance with a small landing zone. Many practitioners evaluate scleral lens clearance by this simple fact—they vary sagittal height based on corneal bearing and air bubble presence from shallow to greater sagittal height until the bearing is gone and/or air bubbles are absent. The size of the landing area/air bubble also can be a guideline; larger areas of bearing or bubble formation require larger step changes in sagittal height. It is important to note that a good lens placement technique is key to preventing “false bubbles” (see chapter V—Management of Scleral Lenses). Bubbles may also form due to an asymmetrical shape of the anterior segment (see step 5 of this chapter). Small bubbles that move may be acceptable as long as they do not cross the pupil area, but large stationary bubbles are

Grading Scale

Vaulting the cornea by creating a certain amount of clearance between the cornea and the back surface of the lens is considered a key element in scleral lens fitting. At the Michigan College of Optometry, a specific scale for scleral lens fitting characteristics has been developed by Lotoczky,



Rosen and Norman (2014). It eloquently shows a variance in central clearance behind the lens of 50, 150, 300, 500 and 600 microns, and it subdivides limbal clearance into 'absent,' 'good' and 'moderate.' All clearances are compared in reference to a standard 300-micron center thickness scleral lens. The full version of the Michigan College of Optometry Scleral Lens Fit Scales is presented in the appendix of this Scleral Lens Guide.

LOTOCZKY, ROSEN AND NORMAN

not. Excessive clearance (500 microns or more), even if no bubbles are formed, can sometimes reduce visual acuity and cause visual disturbances (e.g., a “fish bowl” effect), and potentially it may more easily cause “fogging” (see chapter V).

In keratoconus or other conditions with elevated corneal sagittal heights, larger lens diameters may be required to achieve complete clearance. Some manufacturers of smaller scleral lenses allow a minimal “feather touch central bearing” or “gracing touch” on the top of the cornea in these cases. The goal with these lenses still would be to find the minimum sagittal height that vaults the cornea with little to no apical bearing. Although central clearance is desired at all times, it should be noted that central bearing with scleral lenses typically is well tolerated compared to corneal GP lenses according to many experienced fitters, presumably because scleral lenses usually do not move enough to irritate the apex of the cone. It has been proposed that the fluid layer behind corneo-scleral lenses can serve as a “cushion,” thus supporting the lens. But caution must be taken to ensure there is no corneal staining after removal of these lenses. Sometimes lenses that show corneal bearing also develop lens adhesion (see chapter V). In these cases, all steps necessary should be taken to increase the sagittal depth of the lens.

To further evaluate corneal clearance, an optical section behind the slit lamp can be moved across the eye at a 45-degree angle to observe the post-lens tear film thickness (with and without fluorescein). While the post-lens tear film with corneal GP lenses is hard to image, with scleral lenses this is much easier to observe. A small underestimation of the true clearance should be taken into account with the slit lamp technique (see separate text box on the topic), potentially more so with fluorescein than with white light.

Scleral lenses need time to settle as they can “sink” into the conjunctiva to some degree, but this is subject to high individual variance. It is recommended to wait about 20–30 minutes before evaluating the lens on the eye. It is estimated that various lenses can sink considerably, probably in the 100-200 micron range, but it may be highly variable based on lens design, lens diameter, age of the patient, etc. Most of the sinking seems to take place in the first two hours of lens wear—but the best time to evaluate the overall sinking would be at the end of the day after eight hours or more of lens wear. Hence, when fitting scleral lenses, an extra margin in terms of clearance should be taken into account. Starting off with a slightly excessive clearance may not be a bad idea, to allow plenty of space for the lens to settle (Caroline 2012, Kauffmann 2014). Fenestrated lenses settle more than nonfenestrated lenses. Always choose a large enough corneal clearance to allow the lens to adjust to the ocular surface. The Michigan College of Optometry has developed a useful grading scale for scleral lens evaluation that is specifically helpful for scleral lens clearance evaluation.

Assessment of Corneal Clearance

Vaulting the cornea, by creating a certain amount of clearance between the cornea and the back surface of the lens, is considered the key element in scleral lens fitting. This bridges the cornea, preventing any direct pressure on the often-delicate corneal surface (as often is the case in corneal disease) or creating a moist layer of fluid as in dry eyes. But how to assess the clearance? OCT can be a fantastic help in establishing the exact amount of clearance—measuring it (centrally or limbally) in microns. But most practitioners probably rely on the slit lamp. With that, it should be kept in mind that there is an overall trend for underestimation of the clearance by approximately 50 microns with the slit lamp technique compared to using an ultrasound technique, according to a study by Yeung and Sorbara from the University of Waterloo that used fluorescein and white light. This was the case regardless of prior experience with scleral lens fitting, although in the intermediate and the expert group, significantly less inter-observer variability in clearance estimation was seen (Yeung 2014).

Air bubbles under the lens, if not caused by incorrect lens placement, are a sign of excessive corneal clearance. Many practitioners fit scleral lenses by this simple fact—they vary sagittal height based on corneal bearing and air bubble presence from shallow to greater sagittal height until the bearing is gone and/or air bubbles are absent.

Scleral lenses may need some time to settle as they can “sink” into the conjunctiva to some degree, but this is subject to a high individual variance. It is recommended to wait about 20-30 minutes before evaluating the lens on the eye.

Different central clearances in 50-micron steps, from 150 to 600 microns, are presented (see appendix to this guide).

Peripheral Corneal Clearance

Once corneal clearance has been established over the center of the cornea, then the clearance over the rest of the cornea may need to be adjusted. At this point, the base curve radius of the lens may come into play. Choosing the back optic zone radius of the lens slightly flatter than the flattest keratometry values usually helps alleviate pressure in the peripheral optical zone and limbal area (see chapter III). By adjusting the base curve radius, the back surface shape of the scleral lens can be adjusted to create an alignment tear film reservoir behind the lens. A flatter base curve radius can be used to create limbal clearance as well (see next section in this chapter).

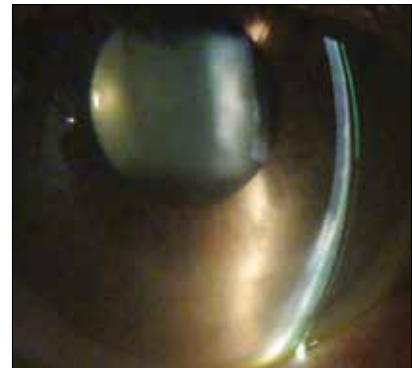
Changing the base curve radius of the lens does mean that the sagittal height of the lens may also be altered. Flattening the base curve will reduce the sagittal height of the lens. This means that the sagittal height may need to be adjusted to compensate for the radius changes. However, many

manufacturers already compensate for this automatically—a change in radius results by default in an alteration in sagittal height (e.g., some manufacturers keep the sagittal height constant although the radius of curvature is changed).

Similarly, sagittal height is also dependent on lens diameter. If the lens diameter is increased while the back optic zone radius is kept stable, the total sagittal height goes up, which can be quite dramatic in terms of an increase in volume. Conversely, a smaller lens decreases the sagittal height if the base curve radius stays the same, unless the manufacturer compensates for this automatically. In short: in principle, one parameter cannot be changed without taking others into account. But to simplify the fitting process, manufacturers can adjust for this automatically. It is advised to check with the manufacturer of the (trial) lenses used to see whether this is the case to avoid double-compensating for sagittal height. What may complicate this step to some degree is that many scleral lenses show some degree of decentration. The amount of clearance superiorly versus inferiorly or nasally versus temporally can therefore differ. Adjusting the lens diameter (see step 1) or the back surface geometry (step 5) can help create better lens centration.

Limbal Clearance

Bridging over the entire cornea is important, as discussed. The limbal area should also be taken



Mini-scleral lens with inadequate vault over corneal graft optic section

Sometimes vision can be improved by reducing lens clearance, sometimes to a minimum. This may give an improvement of one to two lines on the chart, which can be crucial at times, but frequent follow-up eye exams are required.

*Esther-Simone Visser and
Rients Visser*

Stem cells are located in the limbal area and are crucial for corneal health, in particular for processing new epithelial cells, which are then distributed over the entire cornea. Practitioners should strive to avoid mechanical pressure in the limbal area.

Since it is actually the bulbar conjunctiva that is being fit, it is very helpful to look at pressure of the lens periphery on the conjunctiva. Localized areas of the conjunctiva surrounding the limbus can be “whitened” because compression of the lens on the conjunctiva restricts blood flow—which is referred to as conjunctival blanching.

into consideration, as this is where the stem cells are located. Stem cells are believed to be crucial for corneal health, in particular for processing new epithelial cells, which are then distributed over the entire cornea. Limbal pooling may be important to bathe the fragile limbal stem cells. Less clearance in this area may lead to corneal touch upon lens movement. A limbal clearance of 100 microns is often striven for, but this depends on lens size: in corneo-scleral lenses, there may be no or a minimal amount of limbal clearance—as per definition this is where the lens lands. Any type of mechanical pressure and especially limbal staining is unacceptable in all types of scleral lens wear.

Limbal clearance can be achieved in different ways, depending on the manufacturers’ rules and lens design. Basically, choosing a back optic zone radius slightly flatter than the flattest keratometric values helps alleviate pressure in the limbal area. With corneo-scleral lenses it is hard to avoid the limbal zone, since by definition this is where part of the lens’ landing zone is positioned, but the aim is to avoid excessive pressure in the limbal

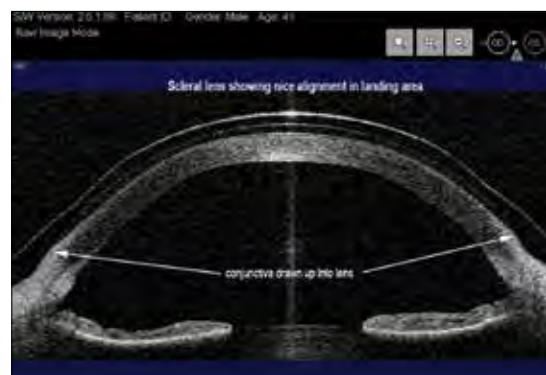
zone. Fluorescein evaluation should reveal minimum bearing in the limbal area, which should be checked regularly for staining. Some corneo-scleral and mini-scleral lens designs come with different transition zone profiles, where the eye care practitioner can choose to increase or decrease the limbal zone clearance. Choosing a different limbal zone profile can alleviate pressure in the corneo-scleral junction area. If persistent bubbles are present in the limbal zone, decreasing the limbal clearance (by lowering the back optic zone radius or by choosing a lower limbal zone profile) may alleviate this problem. OCT imaging can precisely determine the amount of clearance from center to limbus in microns, which could be a useful tool in lens fit assessment.

Step 3: Landing Zone Fit

- How to align the periphery of the lens with (corneo-) scleral shape
- How to evaluate and assess conjunctival blanching

The goal with this zone is to create an alignment with the sclera or corneo-scleral transition (depending on lens type). Most practitioners evaluate the corneo-scleral profile by using the slit lamp with a cross-sectional view of the anterior ocular surface, or by simply observing the anterior ocular shape without magnification by having the patient look downward, to get a first impression of the anterior

The landing zone is closely related to the clearance: a landing zone that is too steep will lift the entire lens off the cornea, creating more clearance, while if there is severe central corneal touch, the lens landing zone will be lifted off the ocular surface, making its fit difficult to assess.



Corneal and limbal clearance visualized with an OCT

GREG GEMOULES

ocular surface shape, possibly using the Meier grading scale as described in chapter II. Others rely fully on trial lenses to observe and potentially adjust the alignment of the landing zone with the anterior ocular shape. Ideally, eye care practitioners in clinical settings would have the instruments available going forward to routinely measure the anterior ocular surface shape to choose the first trial lens to match that. Newer instruments indeed seem to be able to provide such information.

The discussion on lens diameter (step 1) has its main weight—literally—on the parameter of the landing zone fit: the larger the scleral lens, the more lens weight is distributed over a larger area of the sclera. The analogy of snowshoes has been made for large size scleral lenses as compared to stiletto heels for smaller scleral lenses with regard to potential indentation and compression (DePaolis 2009).

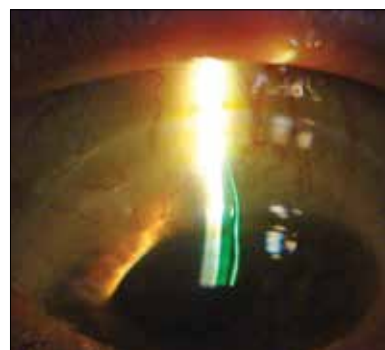Once the trial lens is placed on the eye, the fit is assessed based on how the landing zone bears on the ocular surface. A ring of bearing on the inner part of the landing zone indicates that the landing zone is too flat. Air bubbles in the periphery of the lens also indicate this. Frothing may be present at or under the peripheral lift, indicating the same effect. Additionally, fluorescein evaluation can be helpful in evaluating the landing zone, as reported by some practitioners, but may be of slightly

Manufacturers typically have long-term experience with average landing zone shapes for their particular lens designs. Use the recommended landing zone trial lens as a start, based on their knowledge and insights.

lesser use compared to corneal GP lens fitting assessment.

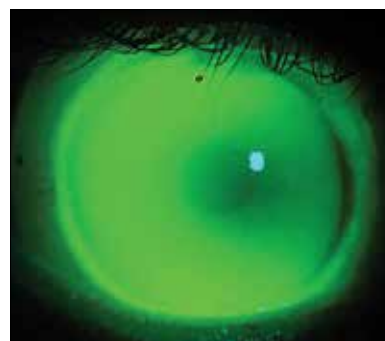For steep lens fits in the landing zone area, the bearing would be on the outer zone, and fluorescein pooling would be visible extending inward beneath the landing zone from the corneal clearance. A steep landing zone will “lift” the entire lens off the cornea, increasing the total vault of the lens.

Since it is actually the bulbar conjunctiva that is being fit, it is very helpful to look at pressure of the lens periphery on the bulbar conjunctiva. Localized areas of the conjunctiva surrounding the limbus

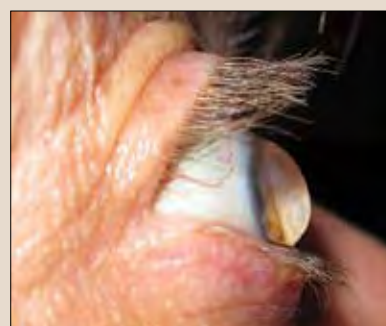
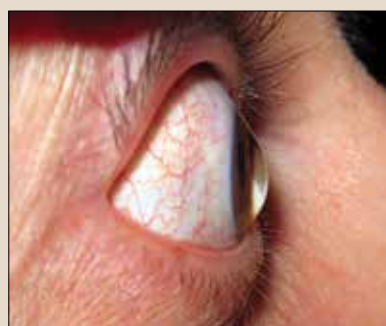
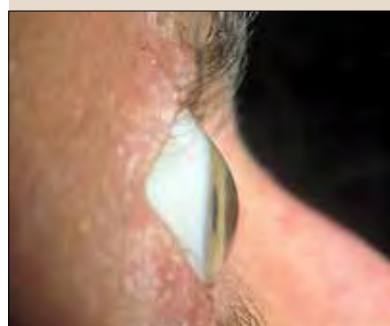STEPHEN BYRNES

Limbal vaulting with mini-scleral lens



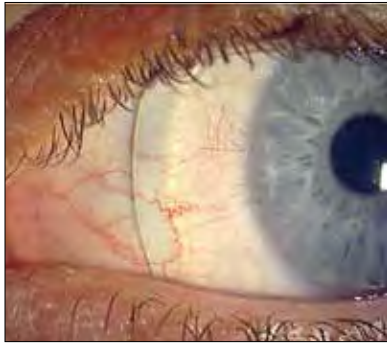
Limbal bearing nasally visible in the fluorescein pattern



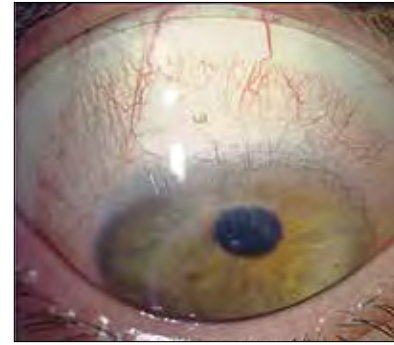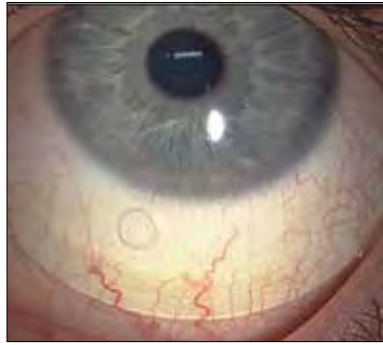GREG DENAEYER

I have found that just observing the eye from the side allows me to determine whether I should start with a diagnostic lens that has either a low, medium, or high amount of sagittal height.

– Greg DeNaeyer



Good distribution of pressure underneath the landing zone area in a large diameter scleral lens



Local blanching under the landing zone of a large scleral lens

VISSER CONTACT LENS PRACTICE

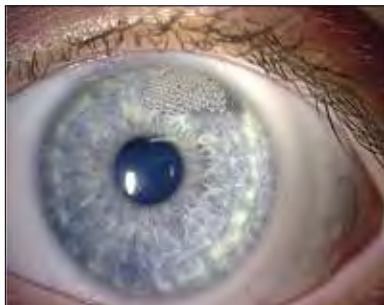
In a grading scale system described by Visser et al for full scleral lenses, a slightly suboptimal clearance that is too low is rated as grade -1 (clearance of 100 or less), while a grade -2 would involve corneal contact. A clearance of roughly 100 to 300 microns is considered optimal. Between 300 and < 500 microns of clearance is considered "big" (grade +1) but acceptable in this scale, while a clearance of more than 500 microns may be considered excessive (grade +2).

In full scleral lenses, an absence of clearance would be grade -2, while between 0 and 100 microns of clearance would be regarded as grade -1. A clearance of roughly 50 to 200 microns is considered optimal, while a clearance of between 200 and < 300 microns may be considered slightly excessive (grade +1). Over 300 microns is considered truly excessive (grade +2). As with any other lens fitting, grade one of any variable is usually considered "acceptable," while a grade two typically means action is required to alleviate the problem.

- Visser et al 2015

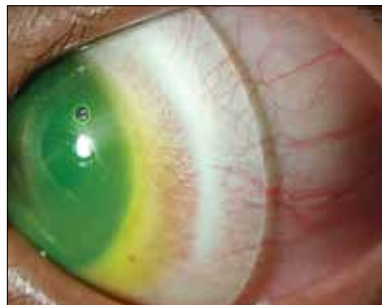can be "whitened" because compression of the lens on the conjunctiva restricts blood flow—which is referred to as conjunctival blanching.

Circumcorneal blanching, or blanching in more than one direction, seems more problematic than a single area of blanching, which may be acceptable at times. Practitioners are advised to observe and assess the blanching in different gaze positions, since decentered lenses can cause a different pattern compared to the static slit lamp position with a straight eye gaze.



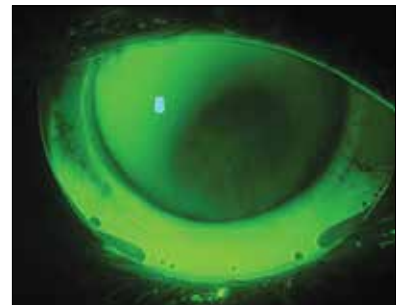
Air bubbles/frothing under scleral lens in the periphery

VISSER CONTACT LENS PRACTICE



Circumcorneal blanching under the landing zone of a large scleral lens
© Universitair ziekenhuis Antwerpen

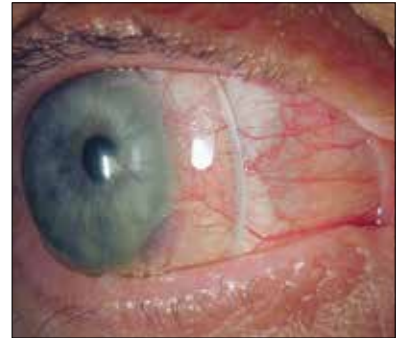JAN PAUWELS



Air bubbles underneath the landing zone periphery

Use the “push-in” method to assess the lens periphery: nudge the lower lid just below the lens edge and indent the sclera gently to assess how much pressure is needed to cause slight stand off. A well fitting edge will need a gentle push. If a hard push is needed, the periphery is tight. If very little pressure is required, the edge may be too flat.

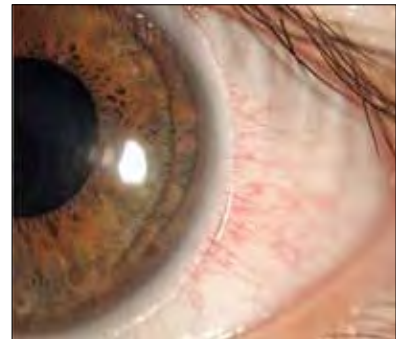Sophie Taylor-West 2009



GREG DENAEYER

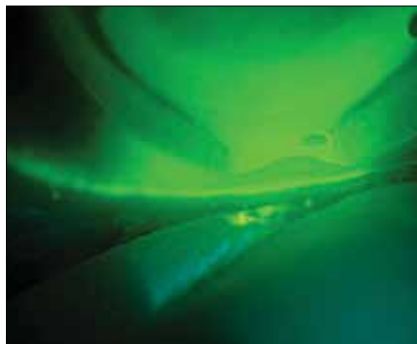
This blanching of the conjunctival vessels results from excessive bearing of the scleral lens on the conjunctiva and is often referred to as compression. Compression typically will not result in conjunctival staining following lens removal, but rebound hyperemia at the location of the compression may be seen.

If the edge of the lens is focally pinching the conjunctival tissue, this will result in “impingement,” which may cause conjunctival staining after lens removal. Long-term impingement may result in conjunctival hypertrophy.



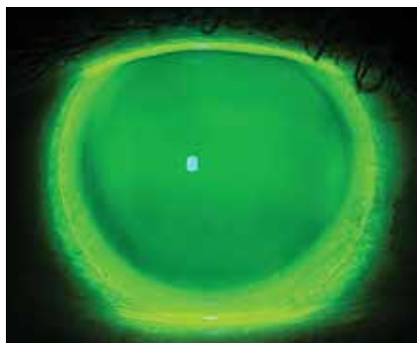
SOPHIE TAYLOR-WEST

Conjunctival impingement



SOPHIE TAYLOR-WEST

The “push-in” method to assess the lens periphery



Impingement ring is seen in this case after lens removal

Step 4: Lens Edge

- How to assess scleral lens edge lift
- How to increase or decrease edge lift

As with GP corneal lenses, a scleral lens needs some edge lift. However, this should not be excessive or it may affect comfort. Although lens movement with scleral lenses is not always possible and is usually not achieved, a good edge lift may promote healthy lens wear and, upon push-up, it would be preferred if the lens showed some mobility. Mini-scleral lenses may sink more into the tissue because they have a smaller landing zone and therefore exhibit less movement. Since the weight of the corneo-scleral lens is balanced on the cornea and sclera, they move more with the blink. Often, full scleral lenses show more movement than mini-scleral lenses because the asymmetry of the peripheral scleral shape may cause the lens to rock.

Too much edge lift can cause lens awareness and discomfort, whereby it is advised to decrease the edge lift by changing the landing zone angle or by choosing a steeper landing zone radius of curvature.

As with some other parameters, the lens edge design is not always variable in all lens designs. If the lens edge is undesirable, the landing zone (step 3) may need to be altered to optimize this if the edge lift itself is fixed.

Compression: Blanching of the conjunctival vessels as a result of excessive bearing of the scleral lens peripheral curve. Compression typically will not result in conjunctival staining following lens removal, but you may observe rebound hyperemia at the location of the compression.

Impingement: The edge of the lens focally pinching the conjunctival tissue. Impingement will result in conjunctival staining after lens removal. Long-term impingement may result in conjunctival hypertrophy.

- Lynette Johns


Low edge lifts can leave a full or partial impingement ring on the conjunctiva after lens removal, and larger blood vessels may be impeded by the lens edge, causing an obstruction in blood flow through the vessel; impingement and compression can occur together at the edge of a tight-fitting lens.

In the absence of any injection or conjunctival staining this may be without consequences, according to experienced scleral lens fitters, but long-term impingement may result in conjunctival staining and possibly hypertrophy.

The edge lift can be assessed in a number of ways. One is to simply observe the edge lift with white light and assess how much it “sinks” into the conjunctiva and/or whether there is a lift-off, in which case a dark band or shadow will be visible under the lens edge. Using fluorescein can also be helpful, as with corneal GP lens fitting. Some practitioners observe the volume of the tear meniscus that is present around the lens edge to evaluate this parameter. OCT imaging may be helpful as well, but care should be taken because an artifact occurs at the edge of the lens due to a difference in index of refraction between the cornea and the contact lens that causes a displacement. The instrument can only account for a single index, so when a lens of a different index is imaged, this artifact results in an overestimation of the OCT image regarding the amount of “sinking” of the lens into the conjunctiva (Sorbara 2015).

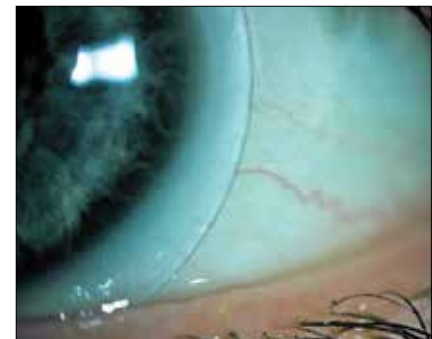
Some practitioners also evaluate the amount of tear film exchange by adding fluorescein to the ocular environment after lens application and waiting to see how long it takes before fluorescein reaches the tear reservoir behind the lens. Sometimes it takes only a minute for fluorescein to reach the post-lens tear film reservoir—but it also can take several minutes to infinity for fluorescein to penetrate behind the lens. Likewise, the time it takes for fluorescein to “empty” from behind the scleral lens if it was added at the time of lens placement may also provide some kind of indication of tear film exchange (Ko 1970, Leach 2014b, Caroline 2014a).

As with some other parameters, the lens edge construction is not always variable in all lens designs. However, it is an important variable to evaluate when assessing the lens fit. If undesirable, the landing zone (step 3) may need to be altered to optimize this if the edge lift itself is unalterable. For tangential landing zone designs,




STEPHEN BYRNES

Lens edge and profile of a mini-scleral lens on extremely keratoconic eye—note the air bubble behind the lens



SOPHIE TAYLOR-WEST



Larger blood vessels may be impeded by the lens edge

the landing zone angle can be chosen with an altered level of incline (seen from a horizontal plane), while for curvature-based landing zones, the periphery of the lens can be altered by increasing or decreasing the radius of curvature in this area. Step 3 and step 4 of this chapter are therefore typically closely related to each other. For more details on specific lens design options, see chapter III of this guide.

The lens, 360 degrees circumcorneally, can fit very differently because of the described asymmetrical nature of the anterior ocular surface. If one or more areas are considerable outliers, either by lift (causing air bubbles) or by impingement/blanching, an asymmetrical lens design may be required (see next step in this chapter).

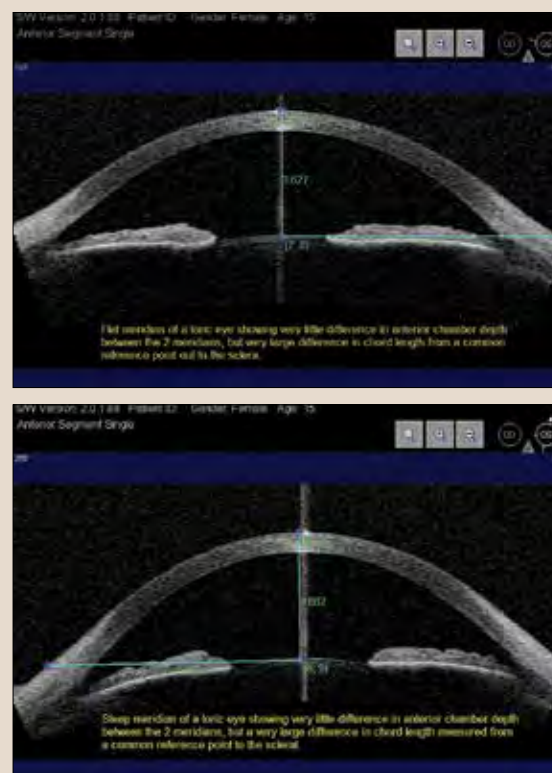
Step 5: Asymmetrical Back Surface Design

- How to choose a toric scleral lens design
- How to choose a quadrant specific scleral lens design

This step is the finishing touch of the scleral lens fit: dealing with asymmetrical lens shapes, such as back toric or quadrant specific surface designs—or even more complex shapes (subdividing the back surface into eight segments, for instance, as some large scleral lens practices do). From clinical experience and from pilot studies on corneal shape as described in chapter II of this guide, it appears that more often than not, the anterior ocular surface is asymmetrical in shape. This means that one or more segments of the sclera are either steeper or flatter than other parts. Oftentimes when a scleral lens is placed on the eye, one segment of the conjunctiva is pressed more, possibly resulting in localized blanching in one or two segments under the lens. This is difficult to deal with: some companies have tried to truncate the lens where the blanching occurs to alleviate pressure in that direction or to “grind” the back surface of the scleral lens to reduce pressure in specific areas. It should be noted, though, that any hand modifications made to the lens reduce reproducibility in the event that the lens needs to be reordered in the future. Toric or quadrant specific scleral lenses could serve as an alternative to overcome

A method to determine where a problem with a scleral lens is located is to have the patient squeeze his or her eyes with the lenses on. A well-fitting scleral lens will cause no symptoms or increased awareness when the patient squeezes his or her eyes. Patients can be very “quadrant specific” after the squeeze test to note the exact areas where there is either impingement or edge lift.

Lynette Johns



Flat and steep meridian of an eye with a toric anterior ocular shape – note the difference in chord length measured from a common reference point: 8.02 mm in the flat meridian (165 degrees) versus 7.34 mm in the steep meridian (75 degrees) with the Zeiss Visante® OCT.

Greg Gemoules

GREG GEMOULES

If you observe 3 o'clock-to-9 o'clock blanching in the absence of pinguecula, order a toric landing zone or decrease the overall sagittal depth of the lens—either by flattening the base curve or adjusting the peripheral curves—provided it does not result in edge lift-off at 12 o'clock and 6 o'clock.

Christine Sindt 2008

this problem in a more structured and controlled way. The toric or quadrant specific portion of these lenses is situated on the landing zone; the optical zone is free of any toricity unless optically a front toric correction is needed and added to the lens.

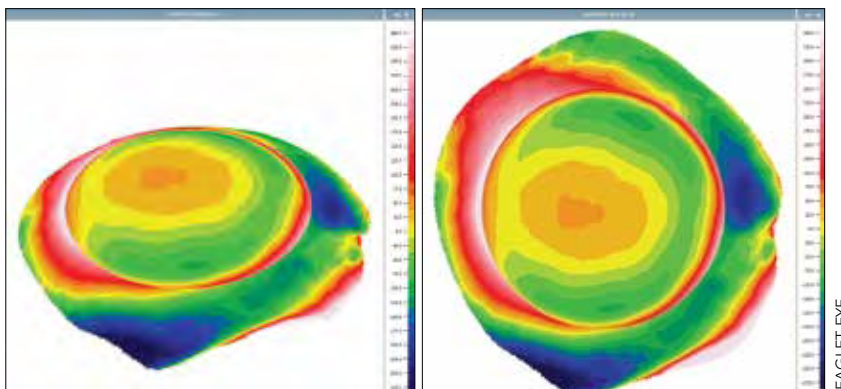
Applying toric and quadrant specific back surfaces to lenses may be one of the more challenging aspects of scleral lens fitting, but at the same time it also is one of the most promising: asymmetrical back surface design scleral lenses can significantly improve scleral lens fit and comfort of wear. This technology has proven to be a successful addition to the standard scleral lenses available. Scleral lenses are usually made of high-Dk materials, but caution should be taken as these lenses can lead to lens flexure on-eye, causing lens warpage. Asymmetrical lenses seem advised to prevent on-eye flexure if the anterior ocular surface shows an irregular shape.

Fitting Toric Scleral Lenses

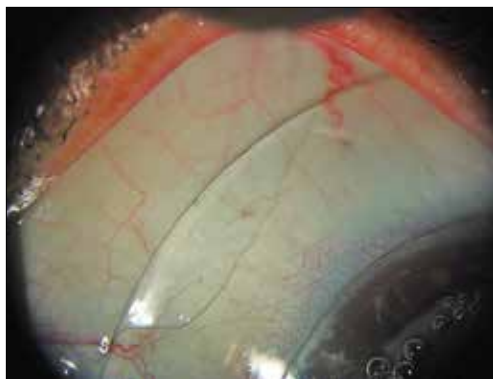Visser et al (2006) reported that toric scleral lenses allow for a more equal distribution of pressure over the sclera, which promotes anterior ocular surface health and improves comfort of lens wear. It also creates a stable lens on the eye. The lens finds its own resting position, just like a back toric corneal GP lens would, although it seems advised to place a mark on the lens so that patients know how to insert the lens correctly. Even after manually rotating the lens, it does return to its natural position on the eye within seconds, according to a study by Visser (2006).

Typically, toric scleral lenses have fixed differences in sagittal height between the two principal meridians. The first and smallest difference between the two principle meridians may be labeled “toric one,” followed by “toric two,” etc. (which does not reflect dioptric differences, as in corneal GP lenses). The exact difference in microns between the two meridians depends on the lens manufacturer and often is confidential. The range can be up to, or more than, 1,000 microns, but based on theoretical considerations of anterior ocular surface shape, the difference between segments can be around 500 microns within the average eye over a 20.0 mm chord and much less for a 15.0 mm chord (see chapter II).

The scleral lens fit should be treated like two standard scleral lenses on one eye: the flat and steep meridians need to be assessed independently of one another in the same fashion one would assess a standard scleral lens. If the fit is unacceptable in one meridian, this meridian should be flattened or steepened accordingly, and the same process should be repeated in the opposite meridian. In some cases more than one meridian needs to be assessed, as will be addressed in the next section. If the lens fit is acceptable, the next step is to evaluate the sagittal height and adjust for that if desired. If the fitting is acceptable, an over-refraction should be performed and a front cylinder can be added if the visual acuity is suboptimal with only a spherical over-refraction. This can be done without any prism ballast, taking the orientation of the lens into



Local differences in scleral shape imaged with the Eye Surface Profiler



Standard concentric symmetrical lens on an asymmetrical sclera

© Universitair ziekenhuis Antwerpen

It is interesting to note that front toric against-the-rule cylinders will naturally align on axis in eyes having eyelid margins that oppose each other in the vertical meridian—as these lenses create thin zones at 6 and 12 o'clock. If the lid margins oppose each other more obliquely, the lens will rotate obliquely. With-the-rule optical corrections rotate off axis in the absence of another form of stabilization. Best success regarding front toric scleral lenses is with against-the-rule cylinders on Caucasian eyes.

Stephen Byrnes

account to determine the lens astigmatism axis as with standard corneal lenses (e.g., LARS rule: left add, right subtract).

This opens up the ability to add front surface optical applications, which are often required for irregular corneas such as, for instance, to correct vertical coma (which occurs frequently in keratoconus).

Fitting Quadrant Specific Lenses

For quadrant specific scleral lenses, typically an empirical lens fitting approach is used: the practitioner uses a standard fitting set and defines the amount and location of lift-off at the edge of the lens in one or more quadrants with the standard concentric symmetrical lens. The amount of lift-off may be judged by using an optical section and a reference, such as the lens thickness. If only one quadrant is altered, in theory it does not matter where that quadrant is placed by the manufacturer, since the lens should find its way on the eye. However, in practice it is seen that these lenses do not move very fast, and typically a mark is placed on the lens just like in toric scleral lenses so that the patient knows how to insert the lens to get it in the right position upon lens placement. To do so, the practitioner must indicate to the manufacturer which quadrant on the eye needs to be adjusted. Also, if more than one quadrant needs to be altered (flattening one quadrant and steepening another, for instance, which is technically doable), the location of the respective quadrants needs to be indicated.

Advanced scleral lens fitters would be able to give the manufacturer a pretty detailed description of the desired quadrant specific design, e.g., the lens needs to be 100 microns steeper in the inferior segment, 200 microns flatter nasally, etc. If desired, front optics can be applied to these quadrant specific lenses, as with toric scleral lenses, taking the LARS rule (see item above) into account regarding lens rotation.

Fitting Front Toric Scleral Lenses

The scleral lens fit in toric or quadrant specific lenses should be evaluated just like a standard concentric symmetrical lens: there should be no or limited blanching or lift of the landing zone on the anterior ocular surface.

If the over-refraction indicates the need to include a cylindrical correction when no toric back surface is desired, a true front toric scleral lens may be needed. These lenses need to be stabilized somehow on the eye, just as front toric corneal GP lenses or soft toric lenses would. Double slab-off ballasting stabilization lenses have been used to stabilize a front toric optical correction on the eye. Eyelid configuration may affect lens rotation and orientation.

I have effectively used pinguecula notches to stop rotation—I get the lens lined up on axis on the eye, mark the lens, then notch the lens at the pinguecula, and I have a non-rotating lens that stays on axis. Truncation at the lower lid does not work very well to stabilize front toric scleral lenses on the eye.

Stephen Byrnes

When ordering these lenses, it is required to take the orientation of the lens into account to determine the lens astigmatism axis as with standard corneal lenses (e.g., LARS rule).

Movement

Scleral lenses typically do not move much, if at all, and the term “scleral lens mobility” may be better nomenclature in this regard. As said previously, corneo-scleral lenses may be slightly more mobile than mini-scleral lenses. As described before, mini-scleral lenses may sink more into the tissue because of their smaller landing zone and therefore exhibit less movement. Because the weight of the corneo-scleral lens

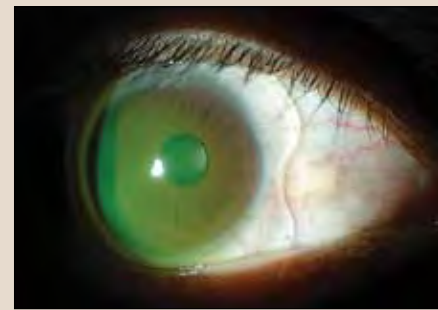
is balanced on the cornea and sclera, they move more with the blink. Contrary, full scleral lenses often show more movement than mini-scleral lenses because the asymmetry of the peripheral scleral shape may cause the lens to rock.

Using the push-up method, the lens should ideally be reasonably mobile. As said previously, spontaneous lens movement upon blinking is not very common and in fact, too much movement can actually be problematic as it can cause lens wear discomfort and dissatisfaction with the scleral lens device.

The landing zone is an important variable concerning lens mobility, and blanching in this area should be avoided. Changing the lens edge does not necessarily have an influence on lens mobility, especially if blanching is present. Scleral lenses with too little apical clearance may “rock” on the central cornea, and this may cause an increase in lens mobility as well as discomfort and decentration. Oftentimes, mobility or movement corresponds to the scleral toricity as well. It may rock vertically along the steepest meridian in the case of a with-the-rule scleral toricity. Changing to an asymmetrical back surface lens design can stabilize the lens.

Overrefraction

Lens power should not be a main consideration during the lens fit. Creating the optimal lens fit is the first and most important objective, which can be challenging enough; refractive power is a later consideration. Usually a lens fit that best respects the shape of the anterior eye is strived for first; only once the most optimal



EMILY KACHINSKY

In some instances, it may be necessary to be creative to fit scleral lens patients—for example, the use of a pinguecula notch. This modification can even be adapted to help accommodate a patient with a filtering bleb.

Emily Kachinsky

A well fit, non-suctioning scleral lens may demonstrate no tear exchange and still be successful. Having tear exchange means that the lens will not suction. Not having tear exchange does not necessarily mean that it will suction. Excessive tear exchange may mean that tear debris will be brought into the lens reservoir.

Lynette Johns

lens fit is reached is an over-refraction required. The over-refraction should be converted back to a vertex distance of zero if this exceeds 4.0 D spherical equivalent.

For this reason a trial lens as close as possible to the patient's needs, or an empirically ordered lens which would allow for a marginal over-refraction, would be preferred. The patient would be able to see with these lenses at the first trial, too, which can be a major psychological advantage.

For over-refraction, some practitioners recommend trial lenses and frames rather than a phoropter. Some eye care practitioners bypass the vertexing in high powers by touching the scleral lens surface with the framed plus or minus lenses from the refraction trial set. The patient does not feel this and the effective vertex distance is zero.

If the base curve radius of the final lens will be ordered differently from that of the diagnostic lens, the standard corneal GP lens "rule of thumb" does apply: 0.10 mm of change in radius is in theory 0.5D change in refraction according to the SAM/FAP rule (SAM: steep add minus, FAP: flatter add plus). See also "the optical zone" section in chapter III of this guide.

Key points:

- *Scleral lenses should have enough total diameter to bear the weight of the entire lens on the anterior ocular surface and to create a sufficient tear reservoir (step 1).*
 - *Creating adequate corneal and limbal clearance is key in (full-) scleral lens fitting (step 2).*
 - *To respect the shape of the anterior surface, aligning the landing zone with the corneo-scleral junction or anterior sclera (step 3) and creating adequate edge lift (step 4) are important. In addition, asymmetrical back surface scleral lens designs may be desired to optimize the lens fit (step 5).*
-

v. Managing Scleral Lens Wear

- How to handle, store and care for scleral lenses
- How to manage the most common scleral lens complications

This section will discuss factors that play a role in scleral lens dispensing, wear, care and follow up. The first part of this chapter will outline handling and storage of scleral lenses plus the role of lens care solutions, followed by the management of scleral lens complications and problem solving in the second part of this chapter.

Handling, Storage and Solutions

Handling

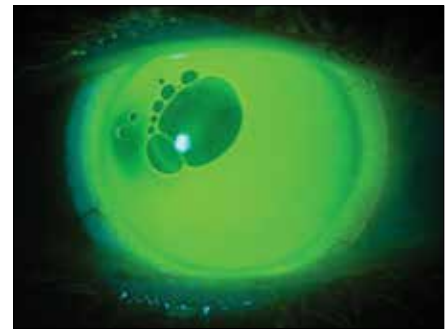
Handling, and especially “bubble free” lens placement on the eye, may be one of the most challenging parts of the scleral lens fitting process for both practitioners and patients. It can be frustrating at times that while achieving technically successful fits and well-tolerated scleral lenses on-eye, patients drop out of scleral lens wear due to handling issues.

Lens Placement

With lens handling, all general hygienic and safety considerations are the same as for other contact lens modalities. This section focuses solely on some specific scleral lens considerations:

1. When placing the lens on the eye, it is of the utmost importance to make sure the patient's face is completely parallel to a horizontal plane, typically a table.
2. The scleral lens should be fully filled with fluid upon lens placement (to a lesser degree for corneo-scleral lenses). Overfilling with a positive meniscus of the fluid on top can help in achieving bubble-free scleral lens application.
3. To support the lens, use the thumb and the index and middle fingers (and/or maybe the ring finger) of one hand like a tripod, or use a plunger for this purpose. Placing the lens on a small, sterile rubber band (as used in orthodontic practice, for instance) situated on the top of the index finger has been proposed to be of help to stabilize the lens on the finger (Woo 2014b).
4. Lift the upper eyelid slightly using the other hand by pushing the eyelid against the superior orbital rim, and gently slide the lens edge under the upper eyelid.
5. Keep the lens in that position, and then slide back the lower eyelid while the patient looks slightly down.
6. Place the lens on the eye (excess fluid from the lens will spill) and let go of the lower eyelid. The eyelid will then slide over the lower part of the lens edge, and the lens is in place.
7. The upper eyelid can be released as well at this point, and if a plunger is used to support the lens, it should be released at this point.

For lens evaluation, the scleral lens should be fully filled with fluid and fluorescein. Extra care should be taken with this, as fluorescein may stain clothing.



Lens placement air bubble beneath the scleral lens

For lens evaluation, the scleral lens should be fully filled with nonpreserved fluid and fluorescein. Extra care should be taken with this, as fluorescein may stain clothing. In the fitting process, allow lenses to settle for 20–30 minutes, but always check patients first using the slit lamp to check for air bubbles, and if present—reinsert the lens. Also, see whether the lens wettability is acceptable and whether there is adequate clearance before referring them to the waiting room, and check for foreign bodies behind the lens as they can irritate the eye but don't necessarily lead to immediate discomfort (as is the case with corneal lenses).

Lens Removal

Removal of lenses is typically done in one of two ways: the manual, two-finger removal method and/or with the use of a plunger; the latter is more often used with larger diameter, full scleral lenses. Oftentimes, both methods are explained to the patient. The first method of choice may be the manual removal method, since no additional accessory is required. If that method for some reason is not successful, for instance in older patients, then the plunger method can be used as an alternative.

For the manual method:

1. Instruct the patient to look slightly down.
2. Slide the lower eyelid gently downward while slightly putting pressure on the eyeball.
3. Gently push the lower eyelid with the index finger underneath the lower edge of the lens.
4. The lower part of the lens will come loose from the ocular surface and will “drop” out of the eye—preferably into the hand of the person removing the lens.

When removing the scleral lens with a plunger:

1. Aim for the lower half of the lens with the plunger.
2. Once the plunger is attached, move it away from the eye and upward. This will break the seal, and the lens can easily be removed.
3. Lift the lens edge from the eye.



GREG DENAEYER

It is critical that the plunger be positioned at the edge of the scleral lens during removal. In this position, as in the picture on the left here, the lens edge is lifted off, releasing the negative pressure, which prevents the lens from pulling on the anterior segment.

Positioning the plunger in the center of the lens during removal, as in the picture on the right here, can put the patient's eye at risk for significant injury. In this position, the scleral lens now becomes a giant plunger. If removal is attempted in this situation, the patient can suffer significant pain, an abrasion, or graft dehiscence in the case of a corneal transplant.

Another situation involves a patient attempting removal with a plunger when the lens is actually not on his or her eye. The patient could easily plunge the cornea or conjunctiva, causing significant injury. With these thoughts in mind, it is critical that patients receive complete instructions on how to use plungers and the dangers that they pose if not used properly.

– Greg DeNaeyer

Upon lens removal, it is important to break the negative pressure beneath the lens, which can also be accomplished by gently pressing on the sclera adjacent to the lens edge, if the initial method is causing problems.

The plunger method has the disadvantage that corneal damage can occur in patients who are attempting to remove the lens while it is no longer in place (and the cornea is directly approached). This is particularly of concern in patients with a corneal transplant, with the risk of corneal grafts being plunged, causing irreversible damage to the eye.

Storage and Solutions

Disinfection

A point that cannot be stressed enough to patients is that the lenses cannot be stored in saline solution overnight because of the risk of microorganism growth and the consequential risk for a microbial keratitis. A contact lens disinfection solution should be used for storage at all times and should be refreshed every night. GP lens disinfection solutions, as well as GP multipurpose solutions, have been recommended by practitioners for scleral lens care. Peroxide systems have also been frequently mentioned as a good alternative to provide a care system that is neutral and safe to the eye while providing good disinfection. Large size containers specially designed for scleral lenses are available for this purpose. Peroxide systems do have the disadvantage that occasionally peroxide can get in the eye, which causes serious irritation, and peroxide is not recommended for storage times longer than one night since there is usually no continuous disinfection action once the solution is neutralized.



Corneal staining underneath a scleral lens as a result of solution-induced toxicity

STEPHEN BYRNES

Applying Scleral Lenses

Scleral lenses should usually be filled with fluid. Nonpreserved saline is most commonly recommended by eye care practitioners when applying scleral lenses to the ocular surface, although in the USA this is not approved by the Food and Drug Administration (FDA) and would be considered an off-label use. Because of the limited tear film exchange behind scleral lenses, exposure to any substance behind the lens is many times greater than with corneal contact lens wear, so many practitioners advise using the most neutral system available. Even the buffer

content in the saline has been reported to cause sensitivity reactions in some eyes (Sindt 2010b). Again, this recommendation is for lens placement on the eye only: for overnight storage, proper disinfection solutions are imperative, and nonpreserved saline solutions are never an alternative.

Rinsing off any conditioning solution, if present, with nonpreserved saline before placement of the lens on the eye has been frequently advised by experienced practitioners. Instruct patients that nonpreserved solutions can only be used for a very limited time once the package has been opened, and single-dose units are highly recommended for this purpose. Aerosols are best avoided as they tend to create small air bubbles and have been reported to be uncomfortable.

Wettability

Wettability issues can affect the success of lens fitting, and for some patients using a conditioning solution instead of the commonly used nonpreserved saline solution upon lens placement is reported to be helpful. But as said, proceed cautiously regarding lens application with these solutions because of the viscosity of and the preservatives in the solution. Filling the lens with a conditioning solution when inserting the lens

is usually not recommended as a standard procedure. Some practitioners advise to gently add saline to the lens when it is removed from the storage case of conditioning solution, leaving as much of the conditioning solution on the lens surface as possible (but releasing the bulk of the conditioning solution). Others recommend rubbing the lens surface with a conditioning solution before lens placement to improve wettability (but, again, not to fill the bowl with the solution). See also the ‘poor wettability’ section later in this chapter on scleral lens management.

Because of the limited tear film exchange behind scleral lenses, exposure to any substance behind the lens is many times greater than with corneal contact lens wear, so many practitioners advise using the most neutral system available.

Cleaning

Cleaning of a scleral lens is usually done manually, using a special cleaning solution. Alcohol-based cleaners have been mentioned as the preferred method by some eye care practitioners, as this is believed to have a positive effect on lens surface wettability. Adequate rinsing is important to remove all cleaning solution from the lens. Occasional cleaning with a 2-component intensive cleaner that contains sodium hypochlorite and potassium bromide is frequently mentioned as an additional procedure that can be effective, especially against protein buildup.

The use of tap water in scleral lens wear is part of an ongoing debate. Tap water use in corneal GP and particularly in orthokeratology lens wear has gained a lot of attention lately. Consensus is that tap water in general poses an extra risk with regard to corneal infections, particularly *Acanthamoeba*. This risk should be countered by the practical and logistical step of avoiding the use of tap water in the daily regimen. Regional differences may play a role in this, as the quality of tap water locally can vary dramatically. Generally, avoiding tap water in the care regimen may reduce the risk of *Acanthamoeba* infection in contact lens wear, including scleral lens wear.

Be aware of what medications patients use with their lenses, since this in itself can alter wettability and can cause toxic reactions.

Jason Jedlicka 2008

Some practitioners recommend using a soft lens multipurpose solution for the cleaning step. The cleaning action may not be as good as with special cleaners, but compatibility of the solution with the eye may be better. This also would be considered off-label use in the USA.

Eye care practitioners should find out what the scleral lens manufacturer’s recommendations and guidelines are for the lens solution system of choice (including the use or avoidance

of tap water in the care regimen), and follow these steps and recommendations meticulously.

For longer storage intervals, e.g., in trial sets and spare lenses, scleral lenses can usually be stored dry. Upon application of the lens, alcohol-based cleaners can be used to optimize wettability.

Scleral lenses are recommended for daily wear only, but overnight use of scleral lenses may be indicated in special cases (Pullum 2007), but only if there are extenuating circumstances, that is, if there is a therapeutic application that makes overnight wear necessary to alleviate pain or to maintain corneal hydration. Since overnight wear has been shown to generate more hypoxic response compared to daily wear, there must be a justifiable reason to do so, such as overnight protection or overnight corneal hydration. In extended lens wear, the lenses still need to be removed regularly for a cleaning cycle and refilled with fresh nonpreserved fluids. Some practitioners work with two pairs of scleral lenses in the event that extended wear is needed: one for the night and one for the day. While one pair is worn, the other pair undergoes a cleaning and disinfection cycle.

Sports

A mentioned advantage of scleral lenses is for vigorous sports, mainly because loss, displacement and decentration are unlikely. For some water sports, scleral lenses are indicated. Scleral lenses will not wash out, absorb contaminants, or change their fitting characteristics during water sports, and even underwater loss of the lens is unlikely. But hygienic considerations apply as with normal lens wear for swimming with lenses, and the increased risk of corneal infection should be explicitly explained to the lens wearer.

Key points—Handling, Storage and Solutions:

- *Handling and “bubble free” lens placement may be one of the most challenging parts of the scleral lens fitting process.*
 - *Practitioners should be careful when instructing patients about the plunger technique to remove scleral lenses, especially in the case of patients with a corneal transplant.*
 - *Neutral solutions are advised upon lens placement because the exposure time of the tear reservoir to the ocular surface is high, but it is imperative to make sure patients understand that these solutions cannot be used for overnight storage.*
-

Scleral Lens Complications

Potential adverse events in scleral lens wear include a number of non-sight threatening complications or situations, referred to in this chapter as “non-severe adverse events”; these are listed in alphabetical order under that subtitle. Although the occurrence of serious adverse reactions in uncompromised eyes wearing scleral lenses, which mainly consists of microbial keratitis, has not been commonly reported in the peer-review literature—it does deserve a separate paragraph in this section, as prevention of this complication should have prime priority in scleral lens practice. Key learning points of each separate item are given directly after each individual section in this part of the guide (rather than at the end of the chapter as in the other chapters in this guide).

Adverse Reactions

Microbial Keratitis and Infiltrates

As stated, serious adverse reactions in uncompromised eyes wearing scleral lenses, such as microbial keratitis, has not been commonly reported in the peer-review literature. Nevertheless, isolated case presentations have indicated that corneal infections do occur in scleral lens wear. Most of the evidence developed so far is limited to relatively small clinical studies conducted by independent researchers, or to large cohort studies from practitioners and entities developing and fitting their own designs, which makes it hard to make a generalized statement. Thus, the actual efficacy and safety of modern scleral lenses in the hands of the average (or even the experienced) contact lens practitioner are unknown. Scleral lens fitting is mostly based on a steep learning curve, and the practitioner’s experience can play a great role in its success. For the domain of fitting scleral lenses, the balance between risk and benefit is more evident at this point in diseased eyes than in non-diseased eyes, considering the unknown consequences of long-term scleral lens wear for the normal, healthy eye versus the benefits in visual acuity gain or comfort. Although unavoidable possibly in certain conditions, extended wear of scleral lenses seems to be related with an increased risk of bacterial keratitis. Oxygen transmissibility of currently manufactured scleral lenses may be marginal at

Special attention should be paid toward hygiene and lens care in scleral lens wear. Since the liquid used in the care regimen to fill the lens' reservoir is typically preservative-free, the highest caution and patient diligence are encouraged. As a potential extra risk factor, the anterior ocular surface is often compromised in scleral lens wearers, by indication.

all times, at least in theory, and is a factor that should be taken into account when fitting scleral lenses (see 'Hypoxia & Edema' section later in this chapter), as well as solution-induced toxicity and the potential to cause corneal staining. In addition, the tear stagnation behind scleral lenses and solution-related toxicity might contribute to higher rates of adverse events, including microbial keratitis, especially considering the already compromised status of many of the corneas.

Rosenthal and Croteau reported the occurrence of four cases of microbial keratitis in patients wearing

the Boston Scleral lens on an extended wear basis (Rosenthal 2005). Noncompliance has also been implicated as the cause for a case of microbial keratitis in a patient wearing scleral lenses for visual rehabilitation because of neurotrophic keratitis secondary to herpes simplex (Zimmerman 2014). Other case reports include an acute red eye in a keratoconus patient wearing a mini-scleral lens (Bruce 2013) and a case of polymicrobial keratitis (Fernandes 2013), a manifestation induced by the presence of multiple microorganisms.

In a case series of five patients in a USA Army burn unit who suffered severe ocular burns, the authors reported two cases of microbial keratitis related to *Pseudomonas* and MRSA (Kalwerisky 2012). However, this is considered a non-standard situation in which many other co-morbidities are implicated. The occurrence of adverse reactions in uncompromised eyes wearing scleral lenses does not seem to be high, based on the reported cases in the peer-review literature and based on clinical input from many experienced scleral lens fitters around the world.

Special attention should be paid toward hygiene and lens care (see the 'Disinfection' and 'Handling' sections in this chapter) in scleral lens wear. Since the liquid used in the care regimen to fill the lens' reservoir is typically preservative-free, the highest caution and patient diligence are encouraged. As a potential extra risk factor, the anterior ocular surface is often compromised in scleral lens wearers, by indication.

Corneal infiltrates have been recorded in scleral lens wear as well. Infiltrates do not necessarily represent corneal infection. They are part of the inflammation cascade, which can be triggered by many things. Location, size and staining with fluorescein of the infiltrate as well as the amount of bulbar redness, pain sensation and anterior chamber reactions are all very important items to exclude a microbial cause of the inflammation and infiltrate. Solution toxicity as well as a lack of tear film replenishment behind the scleral lens may be partly responsible for the development of corneal infiltrates.

In eyes that are void of sensation or have diminished sensation, such as in neurotrophic corneas, conjunctival hyperemia is most likely the only clue that there may be a potential infection. Patients and fitters must be well aware and alert for any signs of redness to rule out infections in these cases. Care must be taken in the fitting of these eyes to prevent fit-associated rebound hyperemia.

Microbial Keratitis and Infiltrates

- *Serious adverse reactions in uncompromised eyes wearing scleral lenses such as microbial keratitis have not been commonly reported in the peer-review literature.*
 - *Special attention should be paid toward hygiene and lens care in scleral lens wear to prevent microbial keratitis.*
-

Non-Adverse Reactions

Air Bubbles

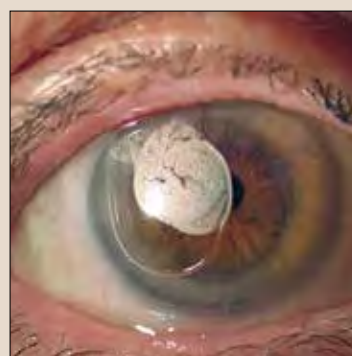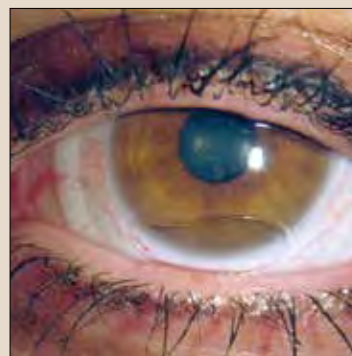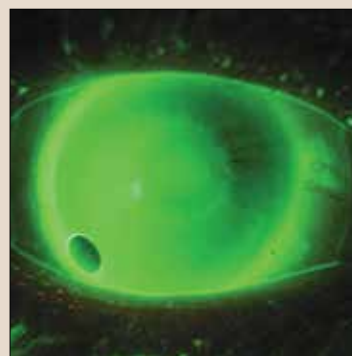
One of the most common “complications” of scleral lens fitting is air bubbles that get trapped behind the lens, caused either by inadequate lens placement or improper lens fit. They can cause discomfort and vision problems and may lead to dry spot formation on the cornea, corneal staining and even corneal dellen formation. One possible cause is a handling issue; see the section earlier in this chapter on lens placement. Another cause is related to lens fit, and this could be addressed by observing the location and size of the bubbles. If air bubble formation happens frequently, then there is a greater chance that this is due to lens fit characteristics. If it happens infrequently, then chances are it is related to the lens placement technique. Following are a few tips and tricks for trying to manage air bubbles behind the lens.

First: bubbles may subside as the lens settles on the eye. It is advised to give it some time. Small bubbles that move behind the lens may be acceptable as long as they do not cross the pupil margin. Bubbles usually float up to the top, regardless of how they formed. Large stationary bubbles are not acceptable. Sometimes bubble formation results from an excessive amount of clearance, but the landing zone and edge lift geometry play a crucial role as well: a suboptimal peripheral lens design that does not follow the shape of the anterior ocular surface optimally can potentially draw in air bubbles under the lens, also referred to as ‘frothing’. Changing the lens design sometimes can be beneficial. Peripheral bubbles can be arch-shaped. Bubbles may more commonly settle temporally than nasally due to the difference in scleral shape in the horizontal meridian (see chapter II). Nasal-inferior bubbles may sometimes be bothersome for patients while reading. Bubbles in the limbal area may indicate too much limbal clearance, and this can be dealt with by adjusting the base curve radius (steepening the base curve) or by decreasing the limbal shape profile, depending on what lens design is used.

Air bubbles are unfortunately not always preventable, especially when the tear reservoir is not uniform, as in corneal ectasia, for instance. Some recommend using a more viscous preservative-free solution to insert the lenses if air bubbles are consistent upon lens placement, but one must be aware of toxic reactions. Lens fenestrations as well as smaller size lenses have been recommended as potential options if air bubble formation is persistent.

A successful fit means the patient is comfortable with no or minimal signs of staining or injection after removal. The best time to observe early complications is after the lens has been worn for three to six hours. Look to see what stains when the lens is removed, after observing how the lens sits on the eye.

Jedlicka et al 2010b



GREG DENAEYER

Scleral lenses with diameters over 18 mm with air bubbles secondary to lens placement

Greg DeNaeyer

Determining the path of entry of the bubbles can be helpful to guide the fit and eliminate bubble formation. The bubble entry point follows tear film exchange. Oftentimes, asymmetrical back surface designs may be needed to “seal” the lens on the ocular surface and to prevent air bubbles from developing behind the lens. See step 5 in chapter IV for more on asymmetrical back surface scleral lenses.

Air Bubbles

- *Teach proper application techniques to prevent lens placement bubbles and/or change the scleral lens fit.*
 - *More viscous preservative-free solutions, asymmetrical back surface designs and (non-) fenestrated lenses have been suggested to potentially be helpful in alleviating the problem.*
-

Bulbar Redness

Bulbar redness as a result of scleral lens wear can occur for a variety of reasons. These include mechanical stress on the conjunctiva, corneal hypoxia (edema), toxic reactions and landing of the lens on the cornea or limbus. Oftentimes, this sign is secondary to a fitting problem, which should be dealt with first. For lenses that adhere (also see the ‘Lens Adhesion’ section in this chapter), redness may occur after lens removal as a rebound effect. Some patients are very sensitive to mechanical stress, but in these cases the redness can reverse itself fairly quickly.

Always exclude external causes of bulbar redness, including microbial involvement, allergic reactions and ocular surface disease, because the redness may not be directly lens related. See “Adverse Reactions” earlier in this chapter for more on microbial keratitis as a potential cause of bulbar redness.

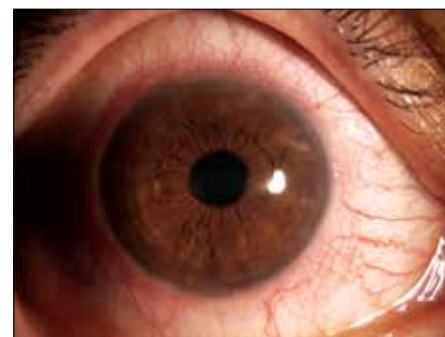Bulbar Redness

- *Conjunctival redness may be, among other things, an indication of a poor lens fit or hypoxic or toxic reactions.*
 - *Always exclude external causes of bulbar redness, as the redness may not be directly lens related.*
-

Conjunctival Blanching, Conjunctival Staining & Pinguecula Management

Conjunctival blanching is caused by localized pressure on the conjunctiva, which can be sectorial or circumcorneal (see chapter IV, step 3). If the blanching is sectorial, this may be the result of an irregular scleral shape. A pinguecula can also cause local pressure and blanching. Loosening the periphery may work in some cases, but more likely asymmetrical back surface scleral lenses or a notch ground into the scleral lens edge may remedy the situation. According to experienced scleral lens fitters, another strategy may be to fit over the pinguecula by using a large diameter scleral lens, thus compressing the pinguecula.

Circumcorneal blanching results from a suboptimal landing zone of the lens (either too steep or too flat). If the entire area beneath the scleral lens landing zone is blanched, increasing the landing zone



Rebound bulbar redness after scleral lens removal

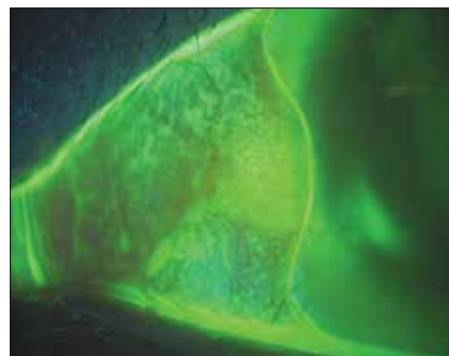
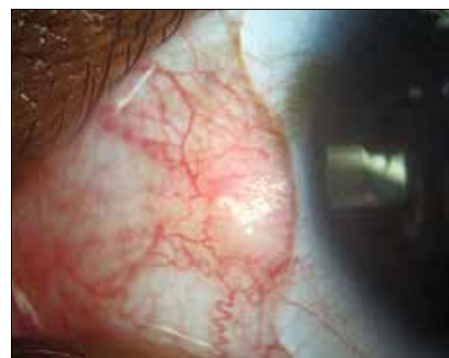SOPHIE TAYLOR-WEST

surface area, essentially by increasing the lens diameter, may help. If the edge of the lens focally pinches the conjunctival tissue, this may result in conjunctival staining after lens removal. The long-term result of this could be conjunctival hypertrophy, which can be reversed by refitting the lens. For full coverage of this topic, see step 3 and 4 of the fitting process of chapter IV.

Since the cornea is less directly involved than the conjunctiva in the location of the scleral lens landing plane, conjunctival staining may be more common than corneal staining. Sometimes conjunctival swelling and hypertrophy occurs. Conjunctival flaps or tears (where the conjunctiva is torn) have been observed occasionally, most probably caused by a sharp or damaged lens edge or by a fingernail.

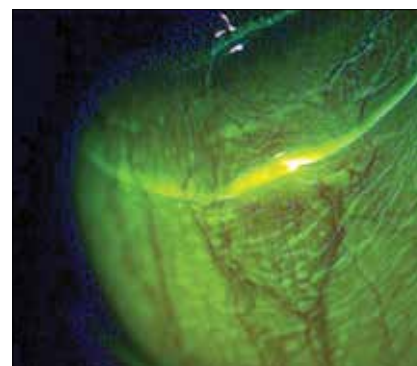
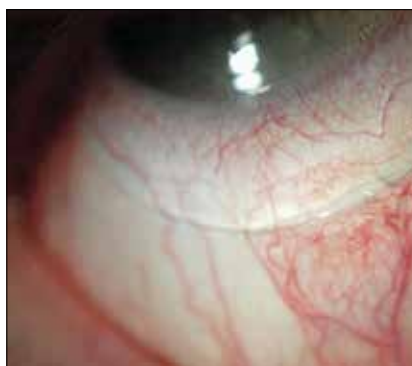Conjunctival staining can be caused by a steep lens edge or possibly by mechanical pressure of the landing zone portion of the lens. The better the lens aligns with the anterior ocular surface, the better the spreading of the pressure, which can decrease the amount of conjunctival staining. This occurs more often in the horizontal meridian. If the staining is present under the landing zone area, this seems to imply that the horizontal meridian is often flatter, causing more mechanical stress in the horizontal meridian. Asymmetrical back surface scleral lenses may be indicated at this point.

If the staining is beyond the scleral lens borders, which can happen particularly in smaller diameter scleral lenses, exposure and therefore dryness issues also may play a role in the etiology of the staining. In corneal GP lens wear, it has been shown that dryness in the nasal and temporal portions immediately adjacent to the lens edge can lead to significant levels of corneal staining (3- and 9-o'clock staining). With scleral lenses, the same effect could occur on the conjunctiva. Covering this area with the landing zone of the scleral lens by using a larger lens diameter may help alleviate the problem.



CHRISTINE SINDT

Inflamed pinguecula fit with a newly fit pinguecula notch—with and without fluorescein



LYNETTE JOHNS

Impingement of the scleral lens on the conjunctiva (left) causing local conjunctival staining and conjunctival hypertrophy (right)

Conjunctival Blanching and Staining

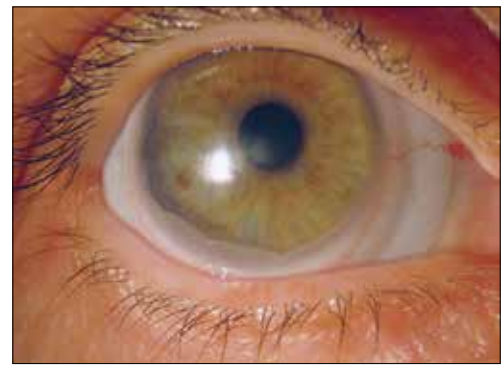- *Conjunctival blanching may be caused by a steep lens edge or by compression of the landing zone portion of the scleral lens on the conjunctiva.*
- *Conjunctival staining can be caused by mechanical pressure or may involve dryness issues.*

Pinguecula Management

- *Loosening the periphery may work in some cases, or asymmetrical back surface scleral lenses.*
 - *Grounding a notch into the scleral lens edge may remedy the situation, or to fit over the pinguecula by using a large diameter scleral lens, thus compressing the pinguecula.*
-

Conjunctival Loose Tissue

In some cases, loose conjunctival tissue (like in conjunctival chalasis) can be drawn beneath the lens because of the negative pressure under the lens. Another term used for this phenomenon is “conjunctival prolapse”, which appears to be more prominent in elderly patients. Loose conjunctiva is sometimes pulled into the transition zone of the lens, and it can, although rare, even appear in the optical zone. In fenestrated lenses, it can even be sucked through the fenestration hole. Excessive conjunctival tissue can be removed surgically, but it does tend to be recurrent (Bartels 2010). Neovascularization has been reported to sometimes develop under the conjunctival flap. And in patients with inflammatory conditions, the flap may adhere to the cornea. It has been suggested that the anterior ocular surface shape may be partly responsible for the location of conjunctival tissue being drawn beneath the lens (Walker 2014a). In other words: if the peripheral cornea and/or sclera is less elevated in the temporal-inferior region of the eye—this is where the conjunctival prolapse would occur. Fitting asymmetrical back surface scleral lenses may help alleviate the problem.



GREG DENAEYER

Loose conjunctival tissue sucked underneath the scleral lens

Conjunctival Loose Tissue

- *Loose conjunctival tissue can get drawn beneath the lens, check for neovascularization and adherence to the cornea under the conjunctival flap.*
 - *Anterior ocular surface shape may be partly responsible for the location of conjunctival tissue being sucked under the lens.*
-

Corneal Staining

Corneal staining may not be a frequent problem in scleral lens wear, presumably because the lens bridges most of, or the entire, cornea. If localized staining appears on the cornea, mechanical involvement due to lens handling should be considered as a possible cause. Handling staining patterns can sometimes occur more in elderly patients, in patients with limited motor skills or in those with poor visual acuity as well as in patients with hypaesthetic or neurotrophic corneas. Upon removal, the scleral lens may scrape the cornea, possibly resulting in a vertical pattern of staining.

Lenses with inadequate clearance over the apex can cause mechanical corneal staining. Incidentally, the scleral lens's fenestration holes can also cause abrasions if the tear reservoir under the lens is too minimal. Increasing the vault of the lens should alleviate this problem. Damaged lenses can also cause corneal abrasions. And large air bubbles have been shown to cause localized areas of dryness, with potential consequent corneal staining as well.

For full corneal staining over its entire surface area, consider toxic reactions or hypoxia as possible causes. As mentioned earlier, the exposure time of the cornea to the fluid beneath the lens is very high, and special caution should be taken regarding any substances used in the lens care regimen. The presence of preservatives and other chemicals on the lens and therefore in the post-lens tear film can easily lead to corneal staining. Check the cornea for very faint patterns of staining, which can potentially cover the entire corneal surface, by removing the lens during check-up visits. Most practitioners advise to always take out the lens with every eye exam and to evaluate the ocular surface with fluorescein.

On the other hand: scleral lens wear does not result in some of the commonly seen types of staining that occur in traditional lens wear, like dehydration staining in soft lens wear and 3- and 9-o'clock staining in corneal GP lens wear. In fact, persistent 3- and 9-o'clock staining in, for instance, a keratoconus patient wearing corneal GP lenses may be a good indication to switch to a scleral lens.

Sometimes “furrow” staining has been recorded in the limbal zone, a well described phenomenon in corneal GP lens wear. Elevations in the corneal surface cause fluorescein to “pool” in the depressed areas. This may be an indication of limbal edema. See “Hypoxia and Edema” section for more on that topic.

Corneal Staining

- *Localized staining: consider handling causes or lens-related issues such as bubble formation or inadequate corneal clearance.*
 - *Full corneal staining: consider toxic reactions or hypoxia.*
-

Discomfort

While in general, comfort of scleral lens wear is recognized specifically as one of the main advantages of the modality, not all scleral fits achieve comfortable lens wear—even though technically they appear to be optimal. Bearing of the lens anywhere in the optical zone area, limbal occlusion or an ill-fitting landing zone may cause discomfort. Changing the lens fit may alleviate the comfort issues.

Although tight lenses will be comfortable at first, patients with scleral indentation, conjunctival impingement and negative pressure buildup will complain of discomfort after lens removal, and they frequently will be unable to wear the lens the next day (DePaolis 2009).

Lens discomfort also frequently is a sign of toxic reactions to preservatives in the solutions used and/or to tear debris in the post-lens fluid reservoir. End-of-day discomfort may be alleviated by using preservative-free comfort drops.

Discomfort

- *Can be related to poor lens fit, but is not always avoidable.*
 - *Could result from toxic reaction to preservatives or debris in the tear reservoir.*
-

Fogging

A fairly common feature in scleral lens wear is a milky and/or particulate debris buildup in the fluid reservoir behind the lens, referred to commonly as “scleral lens fogging,” and this seems to be more prevalent in patients with atopic conditions, ocular surface disease and in post-surgical eyes. The condition of fogging is usually bilateral, but is often significantly worse in one eye than in the other.

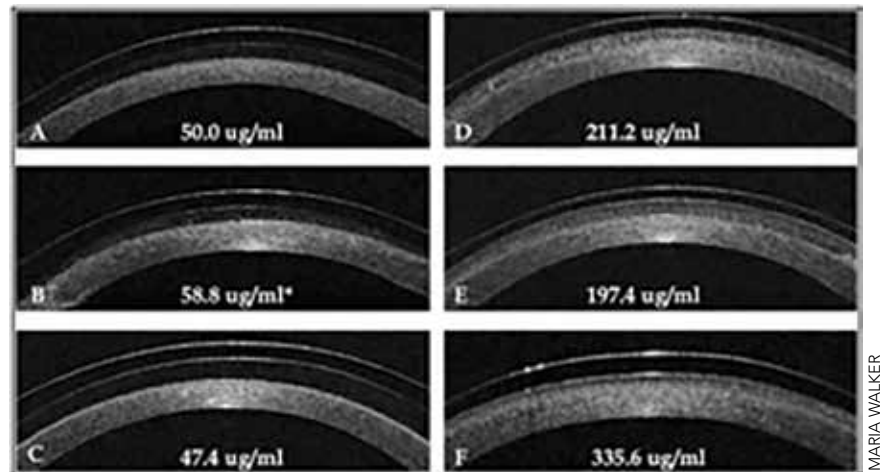
Typically, there seems to be an improvement over time. In some individuals, the first month of lens wear is the worst, then, the frequency of the required lens removal and reapplications becomes less. The condition rarely, if ever, disappears completely on its own though it seems (Caroline 2014c).

Comfort and vision may be affected if this happens. Some patients have to remove, manually clean and replace the lens once or twice a day. In a study by Visser et al (2007b) of patients using large, full size scleral lenses, 50 % of patients could wear the scleral lenses all day without replacing them while the other half had to replace them once or twice a day. This number increased for patients with dry eye conditions.

It may be advised to discuss the possibility of an extra replacement and/or cleaning step during the day with new patients in larger diameter lenses, as they are more likely to accept this extra step if it is explained to them in advance, even though they may not always need it. With this intervention, the wearing time and overall satisfaction can be very good.

Switching to a preservative-free care system can help in managing fogging in scleral lens wear. Also check for other topical treatments the patients may use, as this can interfere with the tear film dynamics. OCT imaging can easily identify the debris buildup behind the lens, oftentimes before either the patient notices a decrease in vision or the eye care practitioner can see it behind the slit lamp.

The problem of tear debris behind the lens seems to be less of an issue with smaller type scleral lenses, such as corneo-scleral lenses, presumably because of the smaller tear reservoir. This was confirmed by studies at the University of Houston (Leach 2014): increased corneal clearance seems to lead to a higher incidence of fogging. The Houston studies also showed a direct relationship of fogging being more common in patients with ocular surface disease, and in terms of lens fit, more fogging was seen in lenses with a tight peripheral fit.



OCT images showing the opacification of tear film reservoirs in six subjects—varying from clear (A-C) and turbid (D-F) tear reservoirs. The values beneath each image show the concentration of esterified cholesterol in each reservoir.

According to Johns (2015) there are three types of debris. These three types can occur together in many cases, but depending on the type, we manage them in different ways. Based on clinical observations, mucus debris typically appears as white, fluffy, small debris that floats in the reservoir. Second, there is fogging associated with atopic disease: a unique type of fogging that appears as much-diluted milk. The third type of debris we observed is an oil droplet form of debris. It looks like olive oil floating over water. It can be a yellowish color, and it is sometimes refractile in nature.



Mucus debris typically appears as white, fluffy, small debris that floats in the reservoir (picture on left). Second, there is fogging associated with atopic disease: a unique type of fogging that appears as much-diluted milk (middle picture). The third type of debris is an oil droplet form of debris (picture on right). It looks like olive oil floating over water. It can be a yellowish color, and it is sometimes refractile in nature.

Debris in the reservoir is a frustrating problem with scleral lenses for both the patient and the fitter. Making every effort to reduce reservoir debris will minimize the risk for scleral lens dropout. It reduces optimal visual acuity and creates significant glare and halos for the patient. Understanding that the debris may be associated with ocular conditions can help reduce the problem when medical management is introduced. Also, manipulating the fit by improving scleral landing zone alignment can block the path of the debris from entering the reservoir. The latter seems to be in concordance with studies by Walker at Pacific University. According to Walker (2014b), the fluid forces associated with a scleral lens pressure system are likely responsible for the introduction of debris into the tear chamber, which causes mid-day fogging in susceptible individuals. The force may be induced by a coup-contracoup movement of a scleral lens that occurs during a blink; as the eyelids close, they apply directional pressure on the lens toward the anterior surface of the eye (retro-pulsion), and as the eye reopens and the pressure is released, the lens rebounds outward and particulate matter is drawn from the peripheral confines of the lens chamber into suspension within the chamber fluid. Over the course of a few hours, the chamber fluid becomes saturated with debris, creating turbidity within the fluid. Walker reports that a lipid substance may be primarily responsible for the post-lens clouding. Considering the hydrophobic nature of the lipids found, it is logical that these molecules would form a precipitate, as they are unable to dissolve in the aqueous solution beneath the lens.

To reduce fogging in these individuals, the design of a scleral lens can be manipulated to discourage the movement of particulate matter under the lens. The observed decrease in fog with limited apical clearance may be the result of thinning of the debris-containing layer in general, as well as the decrease in limbal clearance that narrows the channel for entering debris. More viscous solution may lead to the same effect (to decrease the influx of particulate matter under the lens).

Fogging

- *Have the patient manually clean and reapply the lens once or twice daily.*
 - *Decrease (limbal) lens clearance, and/or change the lens design to discourage the influx of debris under the lens—this includes considering back surface asymmetrical lenses to more closely align to the anterior surface and block the excessive inflow of tear debris.*
-

Giant Papillary Conjunctivitis (GPC)

Because of prolonged periods of lens wear and the potential of surface debris buildup, GPC (also referred to in the literature as contact lens-induced papillary conjunctivitis, CLPC) should be checked for, but it does not seem to be more of a problem than in corneal GP or soft lens wear. GPC is thought to be caused by a

combination of mechanical irritation and/or an allergic or toxic reaction either to substances in contact lens solution or denatured protein on the lens surface. The latter can also cause mechanical problems, since the upper eyelid has to slide over the “rough” lens surface coated with denatured proteins on every single eye blink. Keeping the lens clean and replacing it frequently may help prevent these problems. Also consider asymmetrical back surface scleral lens designs to diminish edge lift-off and mechanical irritation at localized areas. As for the allergic or toxic reaction part: carefully check, monitor and manage the care system regimen.

GPC can cause excessive debris problems on the surface of the lens and in the reservoir as well as wettability problems. Always check for GPC with every eye exam and take preventive measures if indicated, especially if excessive debris is observed.

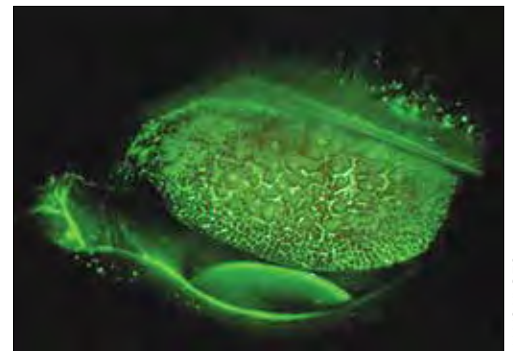
GPC

- *Appears to be no more prevalent in scleral lens wear than in corneal GP or soft lens wear.*
 - *Decrease mechanical irritation and potentially toxic/allergic substances for prevention.*
-

Hypoxia and Edema

Regarding hypoxic stress: it is advised, even with modern lens materials, to keep a close eye on corneal edema and corneal transparency during scleral lens wear. Oxygen supply to the cornea may be insufficient based on theoretical models, if certain criteria of lens thickness, clearance and the Dk of the material are not met. However, it needs to be said that in clinical practice, corneal edema is not often seen, according to scleral lens specialists, and neovascularization, for instance, may turn into ‘ghost vessels’ after switching to scleral lenses.

But studies at both the University of Montreal in Canada (Michaud 2012) and University of Minho in Portugal (Compañ 2014) have found that high-Dk materials, reduced lens thickness and minimal lens clearance should be considered to prevent corneal edema. High-Dk GP lens materials are available today, and should be taken advantage of, but to achieve good oxygen transmissibility (Dk/t), the lens thickness and clearance zone should be regulated as well. Scleral lens fluid filled clearance zones have been reported to, at least in theory, act as an additional filter. Based on these models, decreasing the clearance in addition to the Dk of the material and the thickness of the lens can help improve the Dk/t of the lens system. The University of Montreal model found that the combination of roughly 200 microns of clearance, a lens thickness of 250 microns and the highest-Dk materials available (which are in the 150-170 units range) would just provide adequate oxygen delivery to the cornea to meet the Holden-Mertz criteria to prevent any additional hypoxic stress on the cornea in open eye conditions. Recent studies by Compañ et al (2014) at the University of Minho looked at both a modified theoretical model as well as clinical measurements of corneal edema. Based on these observations, they recommend the scleral lens material to have at least a Dk of 125 with a thickness of 200 microns, and a post-lens clearance of 150 microns to meet an oxygen tension of 55 mmHg—which is considered to be the minimum critical barrier to avoid clinically significant hypoxia, according to the authors. None of the lens combinations tested in their study with a clearance of 350 microns met the 55 mmHg criteria.



GPC in a GP lens wearer

Thus, a lower clearance seems to have a positive effect on the Dk/t of the system, but care should be taken to make sure the ‘vault’ of the lens over the cornea is maintained. Using a different theoretical model Jaynes et al also arrived at similar conclusions that only scleral contact lenses made from the highest Dk material and fitted without an excessive tear reservoir depth may avoid hypoxia (Jaynes 2015, Bergmanson 2015).


Decreasing clearance tends to happen naturally, to some degree, because of the described “sinking” of the lens during daytime wearing hours, causing a natural reduction in clearance. As described, scleral lenses tend to sink quite considerably into the conjunctiva, and this should be taken into account—e.g., a significant margin of error of adequate clearance should be created upon lens fitting.

And as said: thin lenses provide a better Dk/t, but lens flexure causing lens warpage can be a problem with thinner lenses (see ‘Vision Problems’ section in this chapter). Also, high-Dk materials have been reported to result in some debris, wettability and clouding problems. Extra attention should be given to cleaning and maintaining the lens as well as to more frequent lens replacement.

Instruct patients to be wary of decreased visual acuity, especially at the end of the day, to monitor hypoxic conditions. If edematous, the patient may observe rainbow-like patterns around lights known as Sattler’s veil. Neovascularization is rare (also see the ‘Neovascularization’ section in this chapter), but was more of a complication in the time that PMMA materials were used.

Limbal edema is more likely to occur as a result of mechanical stress or lens adhesion (Sindt 2010a), as the oxygen supply is coming from the vasculature of the limbus. If limbal pressure is causing the edema, increasing the limbal clearance should alleviate the problem. If persistent, consider other contact lens options, including corneal GP lenses, piggybacking or hybrid lenses.

A low endothelial cell count may be one of the few scenarios in which scleral lenses may be contraindicated, as the endothelium plays a crucial role in providing the cornea with enough oxygen. It has been reported that an endothelial cell count of less than 800 cells/mm² is where the problems may arise (Sindt 2010a), and endothelial cell counts < 1,000 cells/mm² should be handled with extra care and should not be fitted with scleral lenses to avoid edema. More advanced stages of Fuch’s dystrophy may be a true contraindication for scleral lens wear. Specifically, be careful in corneal transplant cases where graft rejection is a concern: the scleral lens may trigger the problem and may be the tipping point in causing major issues. Especially in these cases, watch for graft swelling observed by the patient as Sattler’s veil or by the practitioner as microcystic corneal edema. Choose in any case an appropriate corneal clearance and a high-Dk/t material, and potentially discontinue lens wear if needed. Modern lamellar corneal transplant technique may have better outcomes in terms of endothelial health than full thickness penetrating keratoplasties (Van Dijk 2014). Eye care practitioners can challenge post-graft corneas with a wearing trial to determine candidacy for scleral lens wear.



Post-corneal graft microcystic edema

Hypoxia and Edema

- *High-Dk materials, reduced lens thickness and minimal lens clearance should be considered to increase the oxygen transmissibility of the system.*
 - *Special care to hypoxic conditions should be taken in post-corneal grafts.*
-

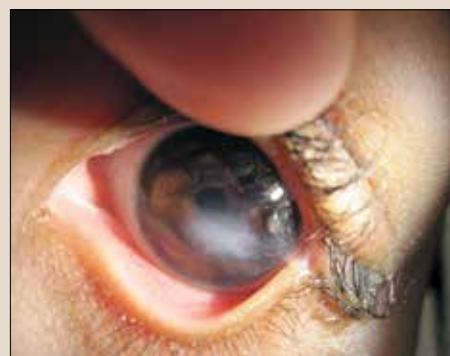Lens Adhesion

Lens adhesion is not a very common finding, but it can occur—more so after prolonged periods of lens wear. Lens adhesion may cause significant discomfort, reduced wearing time and may have a large impact on ocular health if it is not dealt with promptly. Very rarely, lens adhesion could cause damage to the eye, especially in fragile corneas, such as in corneal transplants. Lower corneal clearance lenses and steep landing zones may give rise to more lens adhesion. Altering the lens fit may help overcome this problem. Lens adherence appears to happen more often if the lens creates a seal-off on the ocular surface and in dry eye conditions, such as Sjögren's syndrome. Check the lens fit for excessive pressure on the conjunctiva. Lens flexure can also cause lens adhesion; increase the lens thickness to help avoid this. Lens adherence may also be present because of conjunctival swelling: the lens sinks into the conjunctival cushion. Conjunctival swelling may sometimes result from a lack of limbal clearance. Comfort drops and an extra cleaning step during the day have been reported to be helpful. Fenestrations may also help alleviate the potential negative pressure behind the lens.

When removing a lens that is adhering to the ocular surface, place pressure on the eyeball next to the edge of the lens to release the seal and let fluid get behind the lens. Patients should be instructed with proper removal techniques to avoid adhesion complications, even with well-fitting scleral lenses.

Lens Adhesion

- *Is seen more with lower corneal clearance, steep landing zones, in dry eye conditions and with conjunctival swelling.*
 - *Change lens fit, lens thickness and/or consider fenestrated lenses, comfort drops, extra cleaning and instruct patients with proper removal techniques.*
-



CHRISTINE SINDT

A 2-year-old with neurotrophic keratitis after an anaplastic ependymoma resection left him with a 5th, 6th and 7th nerve palsy. This child had chronic eye infections until fit with a scleral lens for protection. Note the incredible elevation of the scar (picture on the left). Successfully fit with a scleral lens (picture on the right).

– Christine Sindt

Neovascularization

A true complication of scleral lens fitting is corneal neovascularization. A serious problem with PMMA scleral lenses, this phenomenon is quite rare in modern scleral lens wear because of the high-Dk materials available (see the ‘Hypoxia and Edema’ section in this chapter).

Apart from long-term hypoxia, neovascularization can result from prolonged periods of mechanical stress. Always check for mechanical stress on the limbal area—staining, conjunctival blanching, and hyperemia—with every eye exam. Prolonged periods of lens adhesion may also lead to corneal neovascularization. Neovascularization has been occasionally reported beneath loose conjunctival tissue (see the ‘Conjunctival Loose Tissue’ section earlier in this chapter) that can be drawn into the transition zone of the lens, which should be monitored closely for.

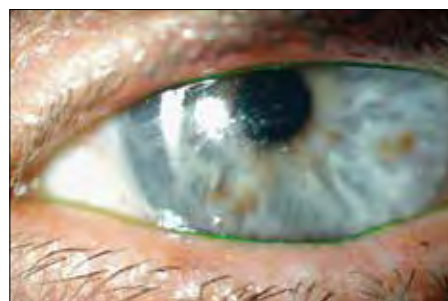Neovascularization

- *Corneal neovascularization can be caused by hypoxia, which was a more common problem with PMMA scleral lenses.*
 - *Mechanical stress, lens adhesion or conjunctival loose tissue may also lead to neovascularization.*
-

Poor Wettability

In cases of severe wettability and anterior surface debris problems, check the Meibomian glands for dysfunction and treat if necessary (Sindt 2010a). Also check for GPC (see the ‘GPC’ section in this chapter), as it may result in excessive surface debris.

Plasma treatment of the lenses as well as peroxide solutions have been promoted in cases with wettability issues. Cleaning the front surface of the lens on-eye with a moistened cotton swab has been proposed as a successful method as well. Switching to preservative-free care system can also reduce the amount of front and reservoir debris in scleral lens wear. Also check for other topical treatments the patients may use, as this can interfere with the tear film dynamics. More frequent replacement of the lenses or a change in lens material may also reduce some of the problems.



Debris on and behind the scleral lens

Poor Wettability

- *Check for Meibomian gland dysfunction and GPC.*
 - *Surface plasma treatment, cleaning the front surface of the lens with a cotton swab and changing the care regimen has been proposed to deal with surface wettability issues.*
-

Vision Problems

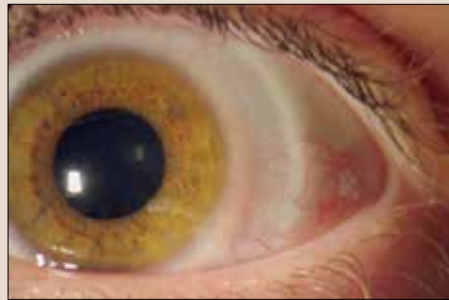
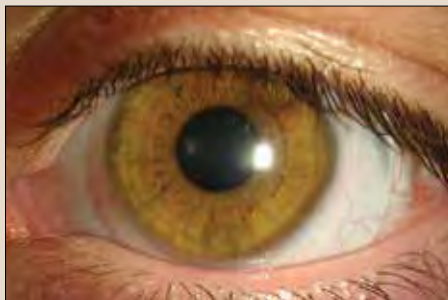Vision problems are commonly caused by air bubbles under the lens, and monocular diplopia may be present. Reinserting the lens properly may alleviate the problem. An excessive tear reservoir can also cause vision-related complaints. Sometimes vision can be improved by reducing the clearance, up to the point where there is a minimal touch on the cornea.

Drying of the lens surface is another fairly common cause of vision problems, usually transient (see the ‘Poor Wettability’ section in this chapter). Extra cleaning, rewetting drops and conditioning solutions should be considered as well as polishing or replacing the lens.

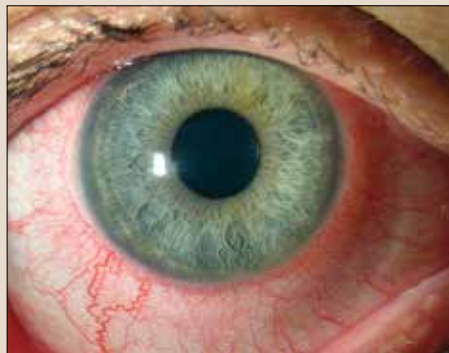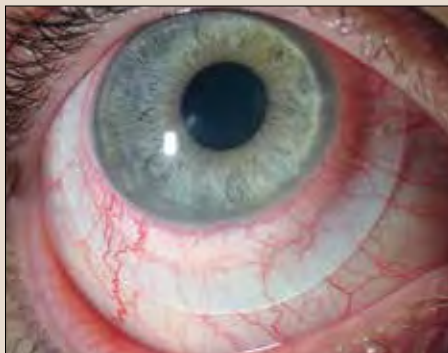Blurred vision after lens removal may be caused by hypoxia and edema or by corneal warpage if the cornea is compromised in some way. Lens flexure can also cause unwanted astigmatism and lens warpage. To check for this, perform corneal topography or keratometry over the lens to determine the optical quality of the front surface. With persistent lens flexure, increase the lens thickness or evaluate need for back surface toric curves for improved scleral alignment.

Vision Problems

- Air bubbles under the lens (change lens fit or lens placement technique), excessive tear reservoir, or wettability issues (consider intensive cleaning, conditioning solutions and surface treatment) are common causes.
 - Lens flexure can lead to warped lenses (increase center thickness of the lens).
-



The above lens (picture on the left) is semi-sealed to the eye, and the patient has comfortable 16-hour-per-day wear time: it shows no blanching during lens wear. After lens removal, an impression ring is visible, with no injection (picture on the right).








GREG DENAEYER

Scleral lenses semi-seal to the eye. Oftentimes, they will settle into the bulbar conjunctiva and leave an impression ring that will be noticeable after removal. This is of no consequence as long as there is no blanching of the vessels. Significant blanching and limbal congestion indicates seal off, and the lens will become unwearable. The lens in the picture on the left has a complete seal, which causes significant injection and irritation, as in the picture on the right. This lens is not wearable for more than a few hours. Flattening the landing zone area will loosen the fit and get the patient back to full-time wear.

– Greg DeNaeyer

SCLERAL LENS FIT SCALES


To accurately estimate the amount of vaulting (clearance) underneath the posterior surface of a scleral lens necessitates a reference point for comparison. Although some have suggested corneal thickness for the reference, we prefer the center thickness (CT) of the lens itself which will be listed on the manufacturer's invoice. In each of the examples below, the CT is 0.30mm (300 microns). In most scleral lens designs, the ideal amount of clearance is about 300 microns.




See reverse side for Limbal Vaulting and Edge Landing example

SCLERAL LENS FIT SCALES

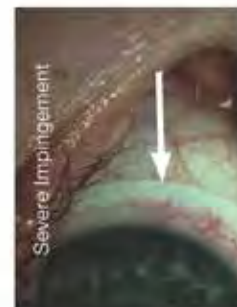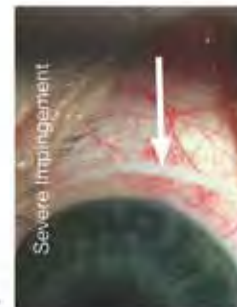
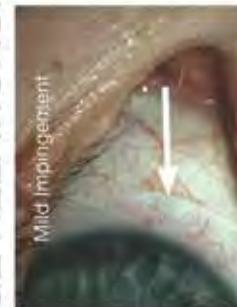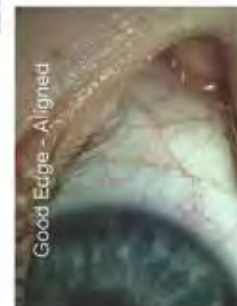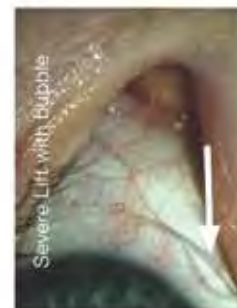CENTRAL VAULTING



LIMBAL VAULTING



EDGE RELATIONSHIP



References

- Achong-Coan R, Caroline PJ, Kinoshita B, Copilevitz L, Lampa M, Kojima R, Andre M (2012) How do normal and keratoconic eyes differ in shape? *Poster GSLs*; January 26-29, Las Vegas, USA
- Baran I, Bradley J, Le HG, Alipour F, Rosenthal P, Jacobs DS (2012) PROSE treatment of corneal ectasia. *Contact Lens & Anterior Eye*; 35(5), 222-7
- Barr JT, Schechtman KB, Fink BA, Pierce GE, Pensyl CD, Zadnik K, Gordon MO, the CLEK Study Group (1999) Corneal scarring in the Collaborative Longitudinal Evaluation of Keratoconus (CLEK) study: baseline prevalence and repeatability of detection. *Cornea*; 18, 34-46
- Bartels MC (2010) *Personal communication*; Deventer Ziekenhuis (NL)
- Bennett ES, Barr JT, Szczotka-Flynn LB (2009) Keratoconus. In: *Clinical Manual of Contact Lenses*. Bennett and Henry, Wolters Kluwer. Chapter 18, 468-507
- Bergmanson JPG (2015a) *Clinical Ocular Anatomy and Physiology*. 22nd ed, Texas Eye Research and Technology Center, Houston, ISBN 978-1-4951-3847-8
- Bergmanson JPG, Ezekiel DF, Van der Worp E (2015b) Scleral contact lenses and hypoxia: theory versus practice. *Contact Lens & Anterior Eye*; 38(3), 145-7
- Bleshoy H, Pullum KW (1988) Corneal response to gas-permeable impression scleral lenses. *Journal of the British Contact Lens Association*; 2, 31-4
- Bokern S, Hoppe M, Bandlitz S (2007) Genauigkeit und wiederholbarkeit bei der klassifizierung des corneo-skleral profils. *Die Kontaktlinse*; 7-8, 26-8
- Borderie VM, Touzeau O, Allouch C, Boutboul S, Laroche L (2009) Predicted long-term outcome of corneal transplantation. *Ophthalmology*; 116, 2354-60
- Bruce AS, Nguyen LM (2013) Acute red eye (non-ulcerative keratitis) associated with mini-scleral contact lens wear for keratoconus. *Clinical & Experimental Optometry*; 92, 245-8
- Caroline PJ, Andre MP (2012) Scleral lens settling. *Contact Lens Spectrum*; 5, 60
- Caroline PJ, Andre MP (2014a) How much tear exchange occurs beneath scleral lenses? *Contact Lens Spectrum*; 7, 64
- Caroline PJ, Andre MP (2014b) Why scleral lenses do not center? *Contact Lens Spectrum*; 8, 56
- Caroline PJ (2014c) Tear film fogging with scleral lenses. *Global Contact*; 68(3), 34-5
- Chan N, Jackson JM (2012) Tear film power and OR effects with scleral lenses. *Contact Lens Spectrum*; 4, 34-7
- Choi HJ, Lee SM, Lee JY, Lee SY, Kim MK, Wee WR (2014) Measurement of anterior scleral curvature using anterior segment OCT; *Optometry & Vision Science*; 91(7), 793-802
- Compañ V, Oliveira C, Aguilera-Arzo M, Molla S, Peixoto-de-Matos SC, Gonzalez-Méijome JM (2014) Oxygen diffusion and edema with modern scleral rigid gas permeable contact lenses. *Investigative Ophthalmology & Vision Science*; 55 (10), 6421-9
- De Brabander J (2002) With an eye on contact lenses technological advancements in medical and optical applications. *PhD thesis*; University of Maastricht, the Netherlands
- DeLoss KS, Fattah NH, Hood CT (2014) Prosthetic Replacement of the Ocular Surface Ecosystem (PROSE) scleral device compared to keratoplasty of the treatment of corneal ectasia. *American Journal of Ophthalmology*; 158(5), 974-82

- DeNaeyer G, Breece R (2009) Fitting techniques for a scleral lens design. *Contact Lens Spectrum*; 1, 34–7
- DeNaeyer G (2010) Modern scleral contact lens fitting. *Contact Lens Spectrum*; 6, 20–5
- DePaolis M, Shovlin J, DeKinder JO, Sindt C (2009) Postsurgical contact Lens fitting. In: *Clinical Manual of Contact Lenses*. Bennett and Henry, Wolters Kluwer. Chapter 19, 508–41
- Doughty MJ, Zaman ML (2000) Human corneal thickness and its impact on intraocular pressure measures: a review and meta-analysis approach. *Survey of Ophthalmology*; 5, 367–408
- Douthwaite WA (2006) The contact lens. In: *Contact Lens Optics and Lens Design*. Elsevier. Chapter 2, 27–5
- Duke-Elder S (1961) The anatomy of the visual system. In: *System of Ophthalmology*. Henry Kimpton.
- Eggink FAGJ, Nuijts RMMA (2007) Revival of the scleral contact lens. *Cataract & Refractive Surgery Today Europe*; 9, 56–7
- Ezekiel D (1983) Gas permeable haptic lenses. *Journal of the British Contact Lens Association*; 6, 158–61
- Fernandes M, Sharma S (2013) Polymicrobial and microsporidial keratitis in a patient using Boston scleral contact lens for Sjogren's syndrome and ocular cicatricial pemphigoid. *Contact Lens & Anterior Eye*; 36, 95–7
- Gemoules G (2008) A novel method of fitting scleral lenses using high resolution optical coherence tomography. *Eye & Contact Lens*; 3, 80–3
- Graf T (2010) Limbal and anterior scleral shape. *Thesis*; Faculty of Optik und Mechatronik HTW Aalen, Germany
- Gungor I, Schor K, Rosenthal P, Jacobs DS (2008) The Boston scleral lens in the treatment of pediatric patients. *Journal of AAPOS*; 3, 263–7
- Hall LA, Young G, Wolffsohn JS, Riley C (2011) The influence of corneoscleral topography on soft contact lens fit. *Investigative Ophthalmology and Vision Science*; 52, 6801–6
- Hall LA, Hunt C, Young G, Wolffsohn J (2013) Factors affecting corneoscleral topography. *Investigative Ophthalmology and Vision Science*; 54, 3691–701
- Hussoin T, Le HG, Carrasquillo K, Johns L, Rosenthal P, Jacobs DS (2012) The effect of optic asphericity on visual rehabilitation of corneal ectasia with a prosthetic device. *Eye & Contact Lens*; 38(5), 300–5
- IACLE - *International Association of Contact Lens Educators* (2006) contact lens course; module 1 (anterior segment of the eye) and module 9 (special topics)
- Jaynes JM, Edrington TB, Weissman BA (2015) Predicting scleral GP lens entrapped tear layer oxygen tensions. *Contact Lens & Anterior Eye*; 38, 44–7
- Jacobs DS (2009) Update on scleral lenses. *Current Opinion in Ophthalmology*; 19, 298–301
- Jedlicka J (2008) Beyond the limbus: corneoscleral lenses in today's contact lens practice. *Review of Cornea & Contact Lenses*; 4, 14–21
- Jedlicka J, Awad O (2010a) Differences in deep lamellar keratoplasties. *Review of Cornea & Contact Lenses*; published online: 17 Jun
- Jedlicka J, Johns LK, Byrnes SP (2010b) Scleral contact lens fitting guide. *Contact Lens Spectrum*; 10, 30–6
- Johns L (2014) Turbid clouding. *I-site newsletter*; Edition 11, posted on Nov 10
- Kalwerisky K, Davies B, Mihora L, Czyz CN, Foster JA, DeMartelaere S (2012) Use of the Boston ocular surface prosthesis in the management of severe periorbital thermal injuries: a case series of 10 patients. *Ophthalmology*; 119, 516–21
- Kauffman MJ, Gilmartin CA, Bennett ES, Bassi CJ (2014) A comparison of the short-term settling of three scleral lens designs. *Optometry & Vision Science*; 91(12), 1462–6

- Ko L, Maurice D, Ruben M (1970) Fluid exchange under scleral contact lenses in relation to wearing time. *British Journal of Ophthalmology*; 7, 486–9
- Kojima R, Caroline PJ, Graff T, Kinoshita B, Copilevitz L, Achong-Coan R, van der Worp E, Lampa M, André M (2013) Eye shape and scleral lenses. *Contact Lens Spectrum*; 4, 38-43
- Kok JHC, Visser R (1992) Treatment of ocular surface disorders and dry eyes with high gas-permeable scleral lenses. *Cornea*; 6, 518–22
- Lim P, Ridges R, Jacobs DS, Rosenthal P (2013) Treatment of persistent corneal epithelial defect with overnight wear of a prosthetic device for the ocular surface. *American Journal of Ophthalmology*; 156(6), 1095-101
- Leach NE, Miller WL, McKinney AM, Polizzi C, van der Worp E, Bergmanson JPG (2014). Midday visual fogging in scleral lens wearers – Does fit matter? *Poster GSLS*; January 25-28, Las Vegas, USA
- Legerton JA (2010) It's time to rethink mini-scleral lenses. *Review of Cornea & Contact Lenses*; published online: 16 Apr
- Lo HL, Shu-I Y, Huey-Chuan C (2014) Scleral contact lenses for visual rehabilitation in keratoconus and irregular astigmatism after refractive surgery. *Taiwan Journal of Ophthalmology*; June, 73–6
- Lotoczky J, Rosen C, Norman (2014) *Scleral Lens Fit Scales*. Michigan College of Optometry.
- Marriott PJ (1966) An analysis of the global contours and haptic contact lens fitting. *The British Journal of Physiological Optics*; 23: 1-40
- Mastrota KM (2014) Changing lives with new scleral lens technology. *Contact Lens Spectrum*; 9, 16
- McMahon J, Pullum KW, Buckley R (2013) Where are we now? Scleral lens contact lens indications and long-term outcome for 1000 referrals. *Poster EAOO meeting*; April 19-21, Malaga (Spain)
- Meier D (1992) Das cornea-skleral-profil – ein kriterium individueller kontaktlinsenanpassung. *Die Kontaktlinse*; 10, 4–11
- Michaud L, van der Worp E, Brazeau D, Warde R, Giasson CJ (2012) Predicting estimates of oxygen transmissibility for scleral lenses. *Contact Lens & Anterior Eye*; 35(6), 266-71
- Michaud L (2013) Support for mini-scleral lenses. *I-site newsletter*; Edition 3, posted on Mar 11
- Millis EAW (2005) Scleral and prosthetic lenses. In: *Medical Contact Lens Practice*. Elsevier. Chapter 12, 121–8
- National Keratoconus Foundation (2015); *NKF website*: www.nkcf.org; accessed Mar 15
- Otten H (2010) True colors—a case report. *I-site newsletter*; Edition 6, posted on June 14
- Pearson RM (2014) *Personal communication*; London (UK)
- Pickles V (2008) Super-size it! Making a difference with scleral lenses. *Boston Update*; Nov, 1–6
- Pullum KW (1997) A study of 530 patients referred for rigid gas permeable scleral contact lens assessment. *Cornea*; 6, 612–22
- Pullum KW (2005) Scleral lenses. In: *Clinical Contact Lens Practice*. Philadelphia, USA: Lippincott, Williams and Wilson. Chapter 15, 629–48
- Pullum KW (2007) Scleral contact lenses. In: *Contact Lenses*. Phillips and Speedwell, Elsevier. Chapter 15, 333-53
- Rosenthal P, Cotter, JM, Baum J (2000) Treatment of persistent corneal epithelial defect with extended wear of a fluid-ventilated gas-permeable scleral contact lens. *American Journal of Ophthalmology*; 1, 33–41

- Rosenthal P, Cotter J (2003) The Boston scleral lens in the management of severe ocular surface disease. *Ophthalmology Clinics of North America*; 16, 89–93
- Rosenthal P, Croteau A (2005) Fluid-ventilated, gas-permeable scleral contact lens is an effective option for managing severe ocular surface disease and many corneal disorders that would otherwise require penetrating keratoplasty. *Eye & Contact Lens*; 31, 130–4
- Rosenthal P, Baran I, Jacobs DS (2009a). Corneal pain without stain: is it real? *The Ocular Surface*; 1, 28–40
- Rosenthal P (2009b). Evolution of an ocular surface prosthesis. *Contact Lens Spectrum*; 12, 32–8
- Rott-Muff D, Keller U, Hausler M, Spinell M (2001) Das cornea-skleral-profil und seine auswirkungen auf die form von weichlinsen. *Die Kontaktlinse*; 5, 26–34
- Sabesan R, Johns L, Tomashevskaya O, Jacobs DS, Rosenthal P, Yoon G (2013) Wavefront-guided scleral lens prosthetic device for keratoconus. *Optometry & Vision Science*; 90(4), 314–23
- Schornack MM (2013) Toric haptics in scleral lens design: a case series. *Poster GSLS*; January 27–29, Las Vegas, USA
- Schornack MM, Nau CG, Brown WL (2014) Estimation of refractive power of scleral/fluid reservoir optical systems in non-parallel scleral lens fits. *Poster GSLS*; January 25–28, Las Vegas, USA
- Schornack MM (2015) Scleral lenses: A literature review. *Eye & Contact Lens*; 41, 3–11
- Segal O, Barkana Y, Hourovitz D, Behrman S, Kamun Y, Avni I, Zadok D (2003) Scleral contact lenses may help where other modalities fail. *Cornea*; 4, 612–22
- Sindt CW (2008) Basic scleral lens fitting and design. *Contact Lens Spectrum*; 10, 32–6
- Sindt CW (2010a) Scleral lens complications slideshow; *SLS website*: www.sclerallens.org/resources
- Sindt CW (2010b) Buffered Saline. *Forum at SLS website*; www.sclerallens.org/buffered-saline, published online: 19 Apr
- Sindt CW (2013) *Personal communication*; Iowa City, IA (USA)
- Smiddy WE, Hamburg TR, Kracher GP, Stark WJ (1988) Keratoconus – contact lens or keratoplasty? *Ophthalmology*; 95, 487–92
- Sorbara L, Maram J, Fonn D, Woods C, Simpson T (2010) Metrics of the normal cornea: anterior segment imaging with the Visante OCT. *Clinical & Experimental Optometry*; 93, 150–6
- Sorbara L, Simpson TL, Maram J, Song ES, Bizheva K, Hutchings N (2015) Optical edge effects create conjunctival indentation thickness artefacts; *Ophthalmic and Physiological Optics*; published online: 9 Febr
- Tan DTH, Pullum KW, Buckley RJ (1995a) Medical applications of scleral contact lenses: 1. A retrospective analysis of 343 cases. *Cornea*; 14(2), 121–9
- Tan DTH, Pullum KW, Buckley RJ (1995b) Medical applications of scleral contact lenses: 2. Gas-permeable scleral contact lenses. *Cornea*; 14(2), 130–7
- Tan B, Graham AD, Tsechpenakis G, Lin MC (2014) A novel analytical method using OCT to describe the corneoscleral junction; *Optometry & Vision Science*, 91(6), 650–7
- Taylor-West S (2009) Lens file: SoClear. *The Optician*; Nov 6, 32–3
- Van der Worp E (2010a) New technology in contact lens practice. *Contact Lens Spectrum*; 2, 22–9
- Van der Worp E, Graf T, Caroline PJ (2010b) Exploring beyond the corneal borders. *Contact Lens Spectrum*; 6, 26–32
- Van der Worp E, De Brabander J, Jongsma F. Corneal topography (2013) In: *Clinical Manual of Contact Lenses*. Bennett and Henry, Wolters Kluwer. Chapter 3, 54–88

- Van der Worp E, Bornman D, Ferreira DL, Faria-Ribeiro M, Garcia-Porta N, González-Meijome JM (2014) Modern scleral contact lenses: A review. *Cont Lens Anterior Eye*; 37, 240-50
- Van Dijk, Baydoun L, Konder RM, Melles GRJ (2014) Contact lenses after keratoplasty. *Contact Lens Spectrum*; 8, 36-42
- Visser ES (1997) Advanced contact lens fitting part five: the scleral contact lens: clinical indications. *The Optician*; Dec 5, 15-20
- Visser ES, Visser R, Van Lier HJ (2006) Advantages of toric scleral lenses. *Optometry & Vision Science*; 4, 233-6
- Visser ES, Visser R, Van Lier HJ, Otten HM (2007a) Modern scleral lenses part I: clinical features. *Eye & Contact Lens*; 1, 13-6
- Visser ES, Visser R, Van Lier HJ, Otten HM (2007b) Modern scleral lenses part II: patient satisfaction. *Eye & Contact Lens*; 1, 21-5
- Visser ES, Van der Linden BJ, Otten HM, Van der Lelij A, Visser R (2013) Medical applications and outcomes of bitangential scleral lenses. *Optometry & Vision Science*; 90, 1078-85
- Visser ES, Soeters N, Tahzib NG (2015) Scleral lens tolerance after corneal cross-linking for keratoconus. *Optometry & Vision Science*; 92(3), 318-23
- Watson PG, Hazleman BL (2013) *The Sclera and Systemic Disorders*. 3rd edition. JP Medical Ltd, ISBN 9781907816079
- Walker MK (2014a) A Proposed mechanism for scleral lens induced conjunctival prolapse. *Poster GSLS*; January 25-28 , Las Vegas, USA
- Walker MK (2014b) Clearing the fog. *I-site newsletter*; Edition 10, posted on Oct 13
- Woo SL (2014a) A very good first impression: using impression technique scleral lens fitting. *I-site newsletter*; Edition 9, posted on Sept 8
- Woo SL (2014b) 10 Do's and don'ts of scleral lenses. *Review of Contact Lenses*; posted on Apr 15
- Yeung D, Sorbara L (2014) Scleral lens clearance assessment by biomicroscopy. *Poster GSLS*; January 25-28 , Las Vegas, USA
- Zhang XR, Zhang ZY, Hoffman MR (2013) Conjunctival thickness measured by optical coherence tomography. *Ophthalmology*; 120(6), 1305
- Zimmerman AB, Marks A. Microbial keratitis secondary to unintended poor compliance with scleral gas-permeable contact lenses (2014) *Eye & Contact Lens*; 40, 1-4



The Scleral Lens Education Society (SLS) is a non-profit organization committed to teaching contact lens practitioners the science and art of fitting all designs of scleral contact lenses for the purpose of managing corneal irregularity and ocular surface disease. SLS supports public education that highlights the benefits and availability of scleral contact lenses.

The SLS is an international association for vision care professionals who develop and/or fit scleral contact lenses. Membership of the SLS is free and open to optometrists and ophthalmologists, students, Fellows of the Contact Lens Society of America, educators and researchers, and other eyecare professionals interested in scleral lenses. SLS provides its members with the latest research, didactic and hands-on educational programs, case reports and a troubleshooting and problem-sharing venue.

The SLS supports all brands and diameters of scleral contact lenses.

In addition to membership, eyecare professionals who have proven themselves in the field of scleral lens fitting can apply for status as a Scleral Lens Specialist, entitling them to be listed as a scleral lens fitter in the database available to the public, and can apply for fellowship of the Scleral Lens Society (FSLs).

For more information, go to: www.sclerallens.org

Supported by an unrestricted
educational grant from:

BAUSCH + LOMB

Boston®

Materials